



Neuroprotective Effect of Ethanol Extract of *Moringa oleifera* Leaf on the Neurofibres of Cerebellum of Quinine-treated Adult Wistar Rats

I. U. Umoh^{1*}, I. A. Edagha¹ and A. N. Aquaisua¹

¹Department of Anatomy, Faculty of Basic Medical Sciences, University of Uyo, Nigeria.

Authors' contributions

This work was carried out in collaboration between all authors. Author IUU designed the study, performed the statistical analysis, wrote the protocol and wrote the first draft of the manuscript. Authors IAE and ANA managed the analyses of the study. Author ANA managed the literature search. All authors read and approved the final manuscript.

Article Information

DOI: 10.9734/AJRIMPS/2018/42865

Editor(s):

(1) Raghvendra Vijay Ramdasi, Professor, Department of Neurosurgery, Jaslok Hospital & Research Centre, Mumbai, India.

Reviewers:

(1) Ghulam Hussain, Government College University Faisalabad, Pakistan.

(2) A. G. Damu, Yogi Vemana University, India.

Complete Peer review History: <http://www.sciencedomain.org/review-history/25877>

Original Research Article

Received 20th May 2018
Accepted 26th July 2018
Published 14th August 2018

ABSTRACT

Aim: The neuroprotective effect of ethanol extract of *Moringa oleifera* leaf on the myelin and neurofibres of cerebellum in quinine treated adult Wistar rats was studied.

Place of Study: Department of Anatomy, University of Uyo, Uyo, Akwa Ibom State, Nigeria.

Study Design: Thirty-five (35) rats weighing between 180 – 200 g were randomly assigned into seven groups of 5 rats each. Group 1 served as the control while Groups 2 - 7 were the experimental groups. Groups 2 - 4 received 10 mg/kg, 20 mg/kg and 30 mg/kg body weight of quinine hypochloride injection intramuscularly eight hourly for seven days, respectively. Animals in Group 5 were administered 250 mg/kg of *Moringa oleifera* leaf extracts and 10 mg/kg body weight of quinine; Group 6, 500 mg/kg of the extracts and 20 mg/kg of quinine while Group 7 received 750 mg/kg of extracts and 30 mg/kg quinine, all for 7 days.

Methodology: Twenty-four hours after final administration, the animals were sacrificed under chloroform inhalational anesthesia. Brain tissues were perfused with phosphate buffered solution,

*Corresponding author: E-mail: umohidorenyin_dr@yahoo.com;

harvested and processed for histomorphological observations of the myelin and neurofibres of the cerebellum using Belcshowsky and Marchi's staining techniques.

Results: Results revealed that quinine caused neuronal distortions, nuclear degenerations, thickened neurofibres, vascular congestions, degenerative changes on myelin with vacuolations in the cerebellum. Incorporation of the *Moringa oleifera* extract to the quinine treated groups revealed neuronal regenerations and restoration of normal cerebellar cyto-architecture.

Conclusion: The results revealed that *Moringa oleifera* leaf extract has neuroprotective effects on the myelin and neurofibres when exposed to quinine neurotoxicity.

Keywords: *Moringa oleifera*; quinine; cerebellum; neurofibres; myelin.

1. INTRODUCTION

Quinine has been a mainstay drug therapy against malaria parasite, the protozoan *Plasmodium* spp. However, the safety profile and effectiveness of the drug differs from one patient to another [1]. An understanding of the molecular basis for these differences in patients could potentially improve treatment strategies. Low therapeutic index of quinine, and adverse effects associated with its use are substantial [2]. The side effects commonly seen at therapeutic concentrations are referred to as cinchonism, with mild forms manifesting as tinnitus, slight impairment of hearing, headache and nausea. Impairment of hearing is usually concentration dependent and reversible [3]. More severe manifestations include vertigo, vomiting, abdominal pain, diarrhea, marked auditory loss, and visual symptoms, including loss of vision. Neurotoxic features of quinine overdose may include ataxia, headache, vertigo, syncope, confusion, and delirium [4,5]. Coma and convulsion may occasionally occur, especially in children with cardio-toxicity [6].

Since the advent of chloroquine resistance malaria and until more recently, quinine has been the main stay in the treatment of severe malaria is the first line drug in West Africa Countries [7]. Recently, quinine is used as an alternative in the treatment of severe or complicated malaria in place of intravenous artesunate [8,9]. In the management of cerebral malaria, quinine is recommended by slow intravenous infusion [10,11]. In pregnancy, quinine is combined with clindamycin to play a critical role in the management of malaria especially in first trimester [9]. The mechanism of action of quinine is not well understood but it is believed to involve the inhibition of parasite haem detoxification in the food vacuole. The mechanism involves the inhibition of hemozoin biocrystallisation in haem detoxification pathway which facilitates the aggregation of cytotoxic haem thereby causing

death of the parasite [12,13]. Quinine highly binds to plasma α -1 acid glycoprotein in a concentration dependent manner. Quinine is metabolized into 3-hydroxyquinine, a pro-oxidant which is of higher toxicity and contributes to the adverse effects observed during quinine administration [14]. Artemisinin-base combination therapies (ACTs) have become the main choice of treatment for malaria. However, quinine is still in use due to obvious reasons regarding the ACTs which include; high cost, unavailability, observable side effects and recently reported resistance of the malaria parasite to some ACT [15,16,17].

Moringa oleifera, commonly called the drum stick, is a tree native to India, but has been planted and domesticated in many other countries, including Nigeria. It is the most known and widely cultivated variety of the genus *Moringa*, family *Moringaceae* [18]. The plant has been widely utilized in traditional medicine and has been reported to have myriads of health benefits. The leaf has been reported to have hypocholesterolaemic property [19], and is known to be helpful to people with diabetes mellitus [20]. The bark is emmenagogue and abortifacient. Flowers are stimulant, tonic and diuretic and increase the flow of bile. The leaf is tasty and is known to ameliorate all kinds of excessive pain and inflammation and used in fattening, anthelmintic cures, hallucinations, dry tumors, hiccough and asthma [21].

A number of natural compounds have been isolated from *M. oleifera* leaves including fully acetylated glycosides bearing thiocarbamates, carbamates or nitriles [22]. Glycosides containing isothiocyanates, malonates and flavonoids have also been identified and isolated in the leaves of the *Moringa* plant [23,24]. Plant glycosides can be used as treatment for cancer or chronic conditions such as high cholesterol and atherosclerosis [19,25]. Flavonoids also have anti-carcinogenic, anti-viral and anti-estrogenic

activities [26]. These phytochemicals can modulate lipid peroxidation involved in atherogenesis, carcinogenesis and thrombosis, and other known properties of free radical scavenging or inhibition of hydrolytic and oxidative enzymes. The bioactive compounds in the leaf of *M. oleifera* make the plant an excellent candidate for nutritional and pharmaceutical supplementation [27].

This research was designed to establish whether *Moringa oleifera* leaf can serve as adjuvant therapy to ameliorate the neuro-toxic effects following administration of quinine via its effect on the neurofibres in the cerebellum of albino Wistar rats.

2. MATERIALS AND METHODS

2.1 Quinine and Plant Materials

Injectable quinine hypochloride was obtained from Buchler GmbH Germany. Appropriate conversion practice was used to calculate the therapeutic and experimental dosages determined per kilogram (kg) body weight of the animals. The injections were given intramuscularly on the thigh of the experimental animals.

The *Moringa oleifera* leaves were collected from a local farm in Uyo, Akwa Ibom State, they were washed clean and transported under hygienic condition. The leaves were identified and authenticated by a taxonomist in the Department of Botany and Ecological Studies, Faculty of Science, University of Uyo, Uyo. *Moringa oleifera* leaf crude extract was prepared by ethanol extraction using Percolation Method described by United States Pharmacopoeia Convention Inc (2000). The concentrated extract was preserved in refrigerator at the temperature of -4°C until commencement of the research.

2.2 Experimental Design

The animals weighing between 180-200 g were sorted into seven groups (1 - 7) with five rats in each group. Group 1 served as the control group and was administered distilled water. Groups 2 - 4 were given 10 mg/kg, 20 mg/kg and 30 mg/kg body weight of quinine hypochloride injection intramuscularly respectively eight (8) hourly for seven days. Groups 5 - 7 were administered with 250 mg/kg of *Moringa oleifera* leaf extract daily + 10 mg/kg of quinine 8 hourly, 500 mg/kg of

Moringa oleifera leaf extract daily + 20 mg/kg of quinine 8 hourly and 750 mg/kg of *Moringa oleifera* leaf extract daily + 30 mg/kg of quinine 8 hourly for 7 days respectively. 24 hours after the completion of the administration of the drug and the extract, the animals were sacrificed under chloroform inhalational anaesthesia and brain tissues were harvested for processing and staining for histomorphological changes.

2.3 Histological Technique for Neurofibres and Myelin

The brain tissues were fixed and processed for histological evaluation of the neurofibres using Bielschowsky's silver staining method for neurofibrils as modified by the method describe by Chan and Lowe [28]. Histological evaluation of the myelin was based on Marchi's method for degenerate myeline as modified by the method describe by Swank and Davenport [29]. Degenerated myelin appeared black while non-degenerated appeared light brown [30].

3. RESULTS AND DISCUSSION

3.1 Effects of Ethanol Extract of *Moringa oleifera* Leaf and Quinine on Neurofibers in Rats

Neurofibers in the cerebellar cortex of control rats showed no extenuation of parallel cerebellar fibers in terms of size and number. The fibers displayed natural orientation parallel to the cerebellar surface (Plate 1). The sections of cerebellum in quinine treated rats from Group 2, 3 and 4 showed mild, moderate and severe degenerative changes respectively. The sections showed focal axonal swellings (spheroid), few areas of degenerated and diffused neurofibers, neurofibrils and lipofuscin shrinkage. The rats in these groups were affected in terms of size, cortical lamination and nerve fiber organization (Plates 2, 3 and 4).

Sections of the cerebellum in Group 5, treated with 10 mg/kg of quinine and 250 mg/kg of *Moringa oleifera* concurrently, revealed normal neurofibers, neurofibrils and lipofuscin within normal cellular architecture. The fibers are in normal orientation parallel to the cerebellar surface (Plates 5). Cerebellar cortex of rats in Groups 6 and 7 treated with 20 mg/kg of quinine + 500 mg/kg of *Moringa oleifera* and 30 mg/kg of quinine + 750 mg/kg of *Moringa oleifera* were moderately affected. There were areas of

degenerated and diffused neurofibres, neurofibrils and lipofuscin (Plates 6 and 7).

Comparison between treated groups revealed that rats treated with 10 mg/kg of quinine and rats treated with 10 mg/kg of quinine + 250 mg/kg of *Moringa oleifera* revealed sections of rat cerebellum with normal morphology in the later compared to the former which showed degenerative changes. Cerebellum of animals treated with 20 mg/kg of quinine revealed a moderate degeneration compared with animals

treated with 20 mg/kg of quinine + 500 mg/kg of *Moringa oleifera* which showed mild degenerative changes. Cerebellar cortex of animals treated with 30 mg/kg of quinine showed a severe neurodegeneration compared with animals treated with 30 mg/kg of quinine + 750 mg/kg of *Moringa oleifera* which revealed a mild neurodegeneration. These are indications of the neuroprotective effect of *Moringa oleifera*, thus damping the neurodegenerative severity of quinine.




Plate 1. Photomicrograph of cerebellar cortex of control group rats revealed wide area of Neurofibres (NF), Neurofibrils (Nf), Lipofuscin (Lf), Neuronal cell (Nc) within normal cellular architecture. Belscholwsky method, Mag. x400




Plate 2. Photomicrograph of cerebellum of group 2 rats treated with 10 mg/kg body weight of Quinine, revealed mild Neurofibres (NF) degeneration, Purkinje cells (PC) Neurofibrils (Nf) degeneration, shrinkage of Lipofuscin (Lf), Neuronal cell (Nc). Belscholwsky method, Mag x400

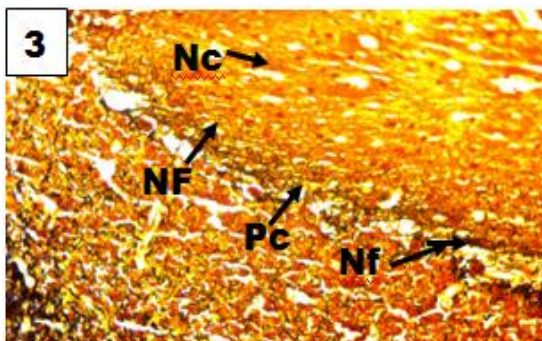


Plate 3. Photomicrograph of cerebellum of Group 3 rats treated with 20 mg/kg body weight of Quinine revealed moderate Neurofibres (NF) degeneration, Neurofibrils (Nf) degeneration, shrinkage of Lipofuscin (Lf), Neuronal cell (Nc). Belcsholwsky method, Mag x400




Plate 4. Photomicrograph of cerebellum of Group 4 rats treated with 30 mg/kg body weight of Quinine revealed severe Neurofibres (NF) degeneration, Purkinje cells (PC), Neurofibrils (Nf) degeneration, shrinkage of Lipofuscin (Lf), Neuronal cell (Nc). Belcsholwsky method, Mag x400

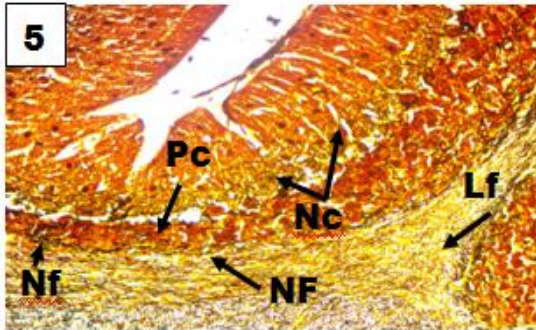


Plate 5. Photomicrograph of cerebellum of group 8 rats treated with 10 mg/kg of Quinine + 250 mg/kg of *Moringa oleifera* stained with Belcsholwsky revealed wide area of Neurofibres (NF), Neurofibrils (Nf), Lipofuscin (Lf) within normal cellular architecture. Mag. (x400)




Plate 6. Photomicrograph of cerebellum of group 9 rats treated with 20 mg/kg of Quinine + 500 mg/kg of *Moringa oleifera* revealed moderate area of Neurofibres (NF) degeneration, Neurofibrils (Nf) degeneration, Neuronal cell degeneration (Ncd) with preserved cellular architecture. Belcsholwsky Method, Mag. (x400)

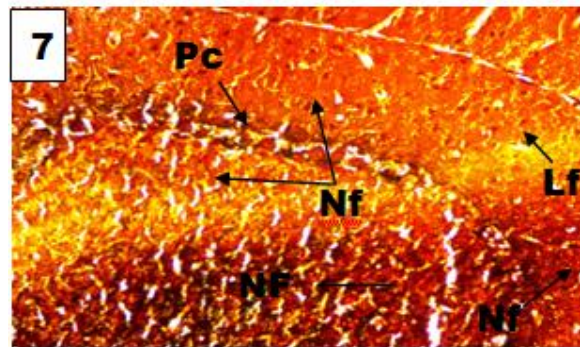


Plate 7. Photomicrograph of cerebellum of Group 7 rats treated with 30 mg/kg of Quinine + 750 mg/kg of *Moringa Oleifera* revealed moderate Neurofibres (NF) degeneration, Neurofibrils (Nf) degeneration, Neuronal cell degeneration (Nc) with preserved cellular architecture as compared to control group. Belcsholwsky method, Mag x400

3.2 Effects of Ethanol Extract of *Moringa oleifera* Leaves and Quinine on Myelin of Rats

The effects of ethanol extract of *Moringa oleifera* leaf and quinine on myelin in the cerebellar cortex of the control group revealed normal cytomorphology of oligodendrocytes and myelination (Plate 1a). The sections of cerebellum in quinine treated rats from Groups 2, 3 and 4 showed mild, moderate and severe degenerative changes, respectively. The degenerated myelin had myelin vacuolation and alteration in the morphology of oligodendrocytes

(Plates 2a, 3a and 4a) as compared to group 1 (Plate 1).

The sections of the cerebellum in Group 5 which was treated with 10 mg/kg of quinine and 250 mg/kg of *Moringa oleifera* concurrently, showed intact myelin with normal morphology of oligodendrocytes (Plates 5a). Cerebellar cortex of rats in Groups 6 and 7 which were treated with 20 mg/kg of Quinine + 500 mg/kg of *Moringa oleifera* and 30 mg/kg of Quinine + 750 mg/kg of *Moringa oleifera* showed moderate degenerative changes in form of myelin vacuolation with no alteration in oligodendrocyte morphology (Plates 6 and 7).

3.3 Discussion

Neurons and their fibres are responsible for carrying information from one point to another. Some of the neurons and nerves may be non-myelinated while some may be myelinated. Just like any other tissues in the body, nerve fibres may be affected by either injuries or toxic substances. The present study demonstrated that quinine exhibited a deleterious effect on the cerebellum of rats as observed in quinine treated groups (Plates 2, 3 and 4). Quinine could have acted as toxins to the cells of cerebellum affecting their cellular integrity and causing a defect in membrane permeability and cell volume homeostasis. Quinine is known to cross

membranes by simple diffusion, thus getting access to the cells [31]. This property of quinine could have been one of the causes of the degenerative changes observed in this study. In cellular necrosis, the rate of progression depends on the severity of environmental insults. The greater the severity of insult, the more rapid the progression of neuronal injury [32]. The principle holds true for toxicological insults to the brain and other organs [33]. The prime candidates for inducing the massive cell destruction observed in neuro-degeneration are neurotoxins [34]. These may be substances present in small amounts in the environment, or even naturally occurring chemicals such as glutamate used by the brain as transmitter

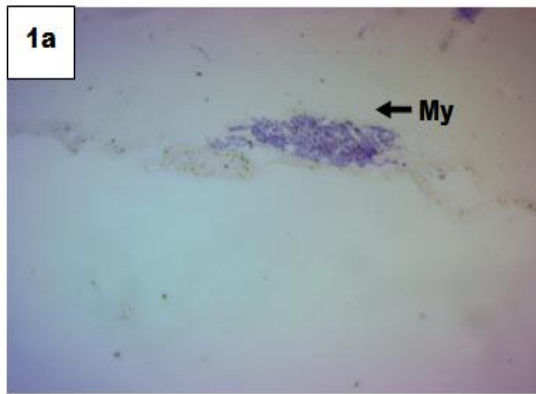


Plate 1a. Photomicrograph of cerebellum of Group 1 rats revealed wide area of normal myelin (My) within normal cellular profile. Marchi's Method, Mag. x400

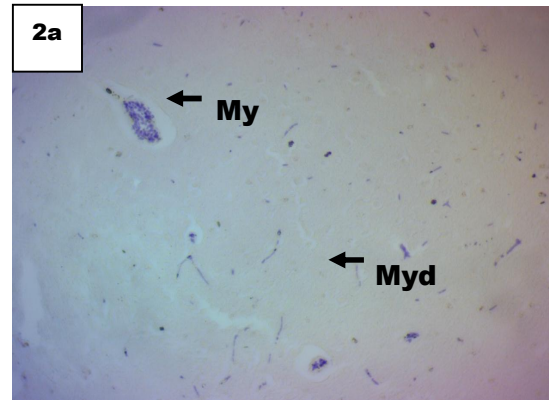


Plate 2a. Photomicrograph of cerebellum of Group 2 rats treated with 10 mg/Kg of Quinine revealed few areas of degenerated myelin (Myd). Marchi's Method, Mag. x400

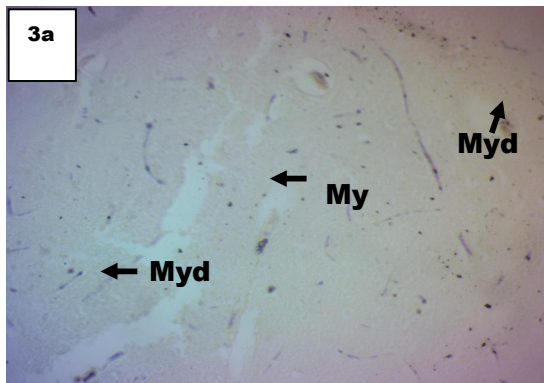


Plate 3a. Photomicrograph of cerebellum of Group 3 rats treated with 20 mg/Kg of Quinine revealed degenerated myelin (Myd). Marchi's Method, Mag. x400

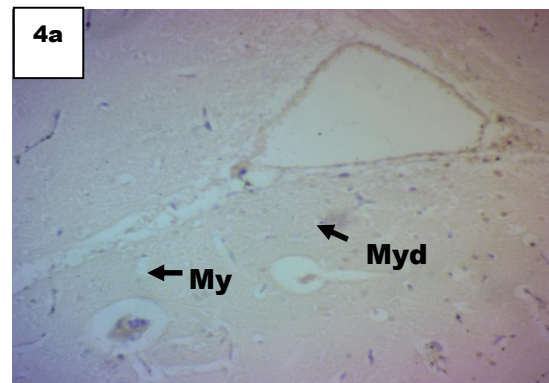


Plate 4a. Photomicrograph of cerebellum of Group 4 rats treated with 30 mg/Kg of Quinine revealed degenerated myelin (Myd). Marchi's Method, Mag. x400

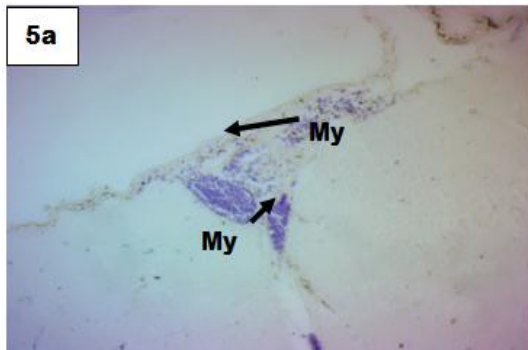


Plate 5a. Photomicrograph of cerebellum of Group 5 rats treated with 10 mg/Kg of Quinine + 250 mg/Kg of *Moringa oleifera* revealed area of normal myelin (My). Marchi's Method, Mag. x400

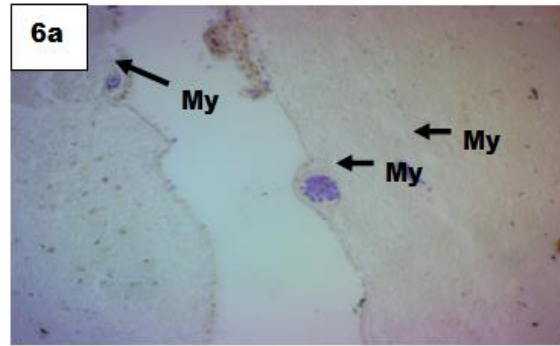


Plate 6a. Photomicrograph of cerebellum of Group 5 rats treated with 20 mg/Kg of Quinine + 500 mg/Kg of *Moringa oleifera* revealed normal myelin (My). Marchi's Method, Mag. x400

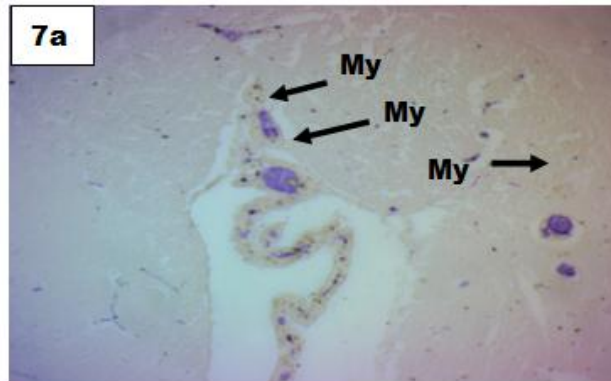

Plate 7a. Photomicrograph of cerebellum of Group 7 rats treated with 30 mg/Kg of Quinine + 750 mg/Kg of *Moringa oleifera* reveal normal area of myelin (My). Marchi' Method, Mag. x400

substances. The latter, when present at a critical level, can be toxic to the brain cells they normally excite [34]. The decrease in neuronal density of quinine treated group as reported in this study may have been as a result of cell death caused by the toxic effect of quinine.

The vacuolations observed in the stroma of the treatment group may be due to quinine interference with lipid metabolism causing a functional derangement followed by alteration in microvasculature leading to perivascular edema, hemorrhage and intravascular fluid accumulation. Quinine intoxication has also been reported to result in the accumulation of lysosomal membranes rich in phospholipids and gangliosides due to the inhibition of lysosomal enzymes [35]. Quinine may be blocking the differentiation of oligodendrocytes precursor cells (OPCs). This is consistent with the study that

inhibitory molecules may have a greater effect when the pool of oligodendrocytes progenitors is reduced [36]. The adverse effects of quinine on the cerebellum observed in this study may underline the possible neurologic symptoms, such as tinnitus, as previously reported [37], following quinine treatment.

In our investigations, the effect of quinine and *Moringa oleifera* concurrent administration on the cerebellum of rats treated with 10 mg/kg of quinine + 250 mg/kg of *Moringa oleifera* revealed normal features. This is an indication that the structural damage that occurred in the cerebellum of rats treated with 10 mg/kg of quinine only was ameliorated when *Moringa oleifera* was administered simultaneously when compared to Groups 1 and 2 as indicated in Plates 1 and 2. This reveals that *Moringa oleifera* was able to restore the neuronal damage caused

by quinine on the cerebellum and this is corroborated by reports stating the anti-toxicity effect of *Moringa oleifera* on cerebral cortex [38]. *Moringa oleifera* leaf extracts exhibited the ability to provide neuronal protection as reflected or observed in Group 5 (Plate 5) when compared to Group 3 (Plate 3). The presence of neurogenic agent in *Moringa oleifera* leaf extracts could ameliorate the process by providing a positive stimulation while damping the neurodegenerative effect of quinine and prevent erratic uncoordinated stimulation. Our observation in Groups 6 and 7 which were treated with 20 mg/kg of quinine + 500 mg/kg of *Moringa oleifera* and 30 mg/kg of quinine + 750 mg/kg of *Moringa oleifera* simultaneously respectively revealed that mild structural damage occurred on the cerebellum of rats in these group. It has already been noted that neurogenesis, one of the key factors which may be involved could only happen a few days after the event of injury [39]. It has been shown that *Moringa oleifera* have a neuroprotective and neuro-regenerative effect on the central nervous system [40]. *Moringa oleifera* is known to be rich in phytochemicals like flavonoids which are strong antioxidants and also is a neurogenic agent [41]. These properties could explain the ameliorative and damping of the neurodegenerative effect of quinine on the neuron integrity, integrity of the neurofibres and neuronal density and the general cytoarchitecture of the cerebellum.

4. CONCLUSION

The study has revealed that *Moringa oleifera* leaf extract has neuroprotective effects on the myelin and neurofibres exposed to quinine neurotoxicity

CONSENT

It is not applicable.

ETHICAL APPROVAL

Ethical approval for the study was obtained from the Ethical Committee of the College of Health Sciences, University of Uyo, Uyo, Akwa Ibom State, Nigeria.

COMPETING INTERESTS

Authors have declared that no competing interests exist.

REFERENCES

1. Berman J. Toxicity of commonly-used antimalarial drugs. *Journal of Infectious Diseases*. 2004;2:171–84.
2. World Health Organization. Severe falciparum malaria. *Journal of Transactions of the Royal Society Tropical Medicine Hygiene*. 2000;94(Suppl 1):S1-S65.
3. Karlsson KK, Hellgren U, Alvan G, Rombo L. Audiometry as a possible indicator of quinine plasma concentration during treatment of malaria. *Journal of Transactions of the Royal Society Tropical Medicine Hygiene*. 1990;84(6):765-767.
4. Wolf LR, Otten EJ, Spadafora MP. Cinchonism: 2 case reports and review of acute quinine toxicity and treatment. *Journal of Emergency Medicine*. 1992;10:295-301.
5. Goldenberg AM, Wexler LF. Quinine overdose: Review of toxicity and treatment. *Journal of Clinical and Experimental Cardiology*. 1988;11:716-718.
6. Batmen DN, Dyson EH. Quinine toxicity. *Adverse Drug Reaction and Acute Poisoning Review*. 1986;5:215-233.
7. World Health Organization. Guidelines for the treatment of malaria. Switzerland; 2006.
8. World Health Organization. Guidelines for the treatment of malaria. 2nd Edition, Geneva; 2010.
9. Achan J, Tibenderana J, Kyabyinze D, Maweje H, Mugizi R, Mpeka B, Talisuna A, D'Alessandro U. Case management of severe malaria- a forgotten practice: Experiences from health facilities in Uganda. *PLOS One*. 2011;6(3):e17053.
10. White NJ, Looareesuwan S, Warrell DA, Warrell MJ, Chanthavich P, Bunnay D, Harinasuta T. Quinine loading dose in cerebral malaria. *American Journal of Tropical Medicine and Hygiene*. 1983; 32(1):1-5.
11. Kyle HH, Fernandez E. Artemisinin derivatives versus quinine for cerebral malaria treatment in African children. *Bulletin of the World Health Organization*. 2009;87:896-904.
12. Fitch CD. Ferriprotoporphyrin IX, phospholipids, and the antimalarial actions of quinoline drugs. *Journal of Life Sciences*. 2004;74(16):1957-72.

13. Alumasa JN, Gorka AP, Casabianca LB, Comstock E, de Dios AC, Roepe PD. The hydroxyl functionality and a rigid proximal N are required for forming a novel non-covalent quinine-heme complex. *Journal of Inorganic Biochemistry*. 2010;21:54-60.
14. Newton P, Keeratithakul D, Teja-Isavadharm P, Pukrittayakamee S, Kyle D, White NJ. Pharmacokinetics of quinine and 3-hydroxyquinine in severe falciparum malaria with acute renal failure. *Journal of Transactions of the Royal Society Tropical Medicine Hygiene*. 1999;93:69-72.
15. Ndem JI, Bassey UE. Parasitaemia reduction and moderately improved haematological indices potentials of *Hippocratea africana* root bark extract in *Plasmodium berghei-berghei* infected mice. *World Journal of Pharmaceutical Research*. 2017;6(4):63-74.
16. Etim OE, Bassey UE, Charles GE, Sambo EE, Akpan EJ. Toxicological evaluation of some Artemisinin Combination Therapies (ACTs) on the kidney and liver of albino wistar rats. *International Journal of Biochemistry Research and Review*. 2016;9(3):1-5.
17. Akpanyung EO, Bassey UE, Usoh IF, Iba IU. Effect of combined administration of Artequin® and Pefloxacin on some indices of liver and renal functions of male albino wistar rats. *Pharmacologyonline*, 2015;3: 84-90.
18. Fugile LJ. The miracle tree: The multiple attributes of Moringa, West African Regional Office, Dakar, Senegal: Church World Service; 2001.
19. Ghasi S, Nwobodo E, Ofili J. Hypocholestromic effects of crude extract of leaf of *Moringa oleifera* Lam in high fat diet fed to Wistar rats. *Journal of Ethnopharmacology*. 2000;69:21-25.
20. Kar A, Choudhary B, Bandyopadhyay G. Comparative evaluation of hypoglycaemic activity of some Indian medicinal plants in alloxan diabetic rats. *Journal of Ethnopharmacology*. 2003;84(1):105-108.
21. Kirthikar KR, Basu, DB. *Indian Medicinal Plants*. Vol. I & II. 2nd ed. Delhi: Periodical Experts Book Agency; 1986.
22. Faizi S, Siddiqui BS, Saleem R, Siddiqui S, Aftab K, Gilani AH. Fully acetylated carbamate and hypotensive thiocarbamate glycosides from *Moringa oleifera*. *Journal of Phytochemistry*. 1995;38:957-963.
23. Miean HK, Mohamed S. Flavonoid (Myricetin, Quercetin, Kaempferol, Luteolin, and Apigenin) content of edible topical plants. *Journal of Agricultural and Food Chemistry*. 2001;49:3106-3112.
24. Bennett RN, Mellon FA, Foidl N, Pratt JH, Dupoint SM, Berman J. Toxicity of commonly-used antimalarial drugs. *Travel Medicine and Infectious Diseases*. 2004;2:171-84.
25. Chumark P, Khunawat P, Sanvarinda Y, Phornchirasilp S, Church MW, Parent-Jenkins L, Rozzelle AA, Eldis FE, Kazzi SNJ. Auditory brainstem response abnormalities and hearing loss in children with craniosynostosis. *Pediatrics*. 2007; 119:e1351-e1360.
26. Havsteen BH. The biochemistry and medical significance of the flavonoids. *Journal of Pharmacological and Experimental Therapeutics*. 2002;96:67-202.
27. Siddhuraju P, Becker K. Antioxidant properties of various solvent extracts of total phenolic constituents from three different agro-climatic origins of drumstick tree (*Moringa oleifera* Lam.). *Journal of Agricultural and Food Chemistry*. 2003;15:2144-2155.
28. Chan KK, Lowe J. Technique in neuropathology. In: Bancroft JD, Gamble M, Eds. *Theory and Practice of Histological Techniques*, 5th Edn. Edinburgh: Churchill Livingstone. 2002;371-414.
29. Swank RL, Davenport HA. Chlorate-osmotic formalin method for degenerating myelin. *Stain Technology*. 1935;10:87-70.
30. Marchi V. Sulle degenerazioni discendenti consecutivea lesioni in diverse zone della corteccia cerebrale. *Riv Sper Freniatr Med Leg Alien Ment*. 1970;14:1-49.
31. Lüllmann H, Lüllmann-Rauch R, Wassermann O. Lipidosis induced by amphiphilic cationic drugs. *Journal of Biochemical Pharmacology*. 1978;27:1103-1108.
32. Ito U, Sparts M, Walker JR, Warzo A. Experimental cerebral ischemia in magolian gerbils. Light microscope observation. *Acta Neurophatol*. 1975;32: 209-223.
33. Martins LJ, Al-Abdulla NA, Kirsh AM, Sieber FE, Portera-Cailliau C. Neurodegeneration in excitotoxicity, global cerebral ischemia and target deprivation: A perspective on the contributions of

- apoptosis and necrosis. Brain Research Bulletin. 1978;46:281-309.
34. Waters CM. Glutamate induced apoptosis of striatal cells in rodent model for Parkinsonism. Neuroscience. 1994;63:1-5.
35. DeGroot PG, Elferink RO, Mariastruland A, Westeveld A, Khan PM, Tager JM. Inactivation by chloroquine of α -galactosidase in cultured human skin fibroblasts. Experimental Cell Research. 1981;136:327-333.
36. Armstrong DM, Cogdell B, Harvey RJ. Discharge patterns of Purkinje cells in cats anaesthetized with alphachloralose. Journal of Physiology. 1979;291:351-366.
37. Manolette RR. Chloroquine/Hydroxychloroquine toxicity. e-Medicine Journal. 2001;2(5):17-21.
38. Owolabi J, Williams F. Histological assessment of *Moringa oleifera* anti-toxicity actions against lead-induced damage to the cerebellar cortex in animal models. International Journal of Moringa and Nutraceutical Research. 2014;1(1):75-84.
39. Ogilta K, Nishiyama N, Sugiyama C, Higuchi K, Yoneyama M, Yoneda Y. Regeneration of granule neurons after lesioning of hippocampal dentate gyrus: Evaluation using adult mice treated with trimethyltin chloride as a model. Journal of Neuroscience Research. 2005;82:609-621.
40. Kirisattayakul W. *Moringa oleifera* Lam mitigates oxidative damage and brain infarct volume in focal cerebral ischemia. American Journal of Applied Science. 2001;9(9):1457-1463.
41. Umoh IU, Ekanem AU, Bassey UE, Ufot AL. Ameliorative effect of *Moringa oleifera* leaves extract on the intracranial auditory relay centre (Inferior Colliculus) of male albino wistar rats with quinine induced toxicity. International Journal of Pharmaceutical Research and Application. 2017;2(1):10-15.

© 2018 Umoh et al.; This is an Open Access article distributed under the terms of the Creative Commons Attribution License (<http://creativecommons.org/licenses/by/4.0>), which permits unrestricted use, distribution, and reproduction in any medium, provided the original work is properly cited.

Peer-review history:

The peer review history for this paper can be accessed here:
<http://www.sciencedomain.org/review-history/25877>