



## Bulbar urethral stricture: How to optimise the use of buccal mucosal grafts

Jonathan N. Warner, Eric S. Wisenbaugh & Francisco E. Martins

To cite this article: Jonathan N. Warner, Eric S. Wisenbaugh & Francisco E. Martins (2016) Bulbar urethral stricture: How to optimise the use of buccal mucosal grafts, Arab Journal of Urology, 14:2, 78-83, DOI: [10.1016/j.aju.2016.01.002](https://doi.org/10.1016/j.aju.2016.01.002)

To link to this article: <https://doi.org/10.1016/j.aju.2016.01.002>



© 2016 Arab Association of Urology



Published online: 05 Apr 2019.



Submit your article to this journal [↗](#)



Article views: 353




View related articles [↗](#)



View Crossmark data [↗](#)



Citing articles: 1 View citing articles [↗](#)



ONCOLOGY/RECONSTRUCTION  
REVIEW

# Bulbar urethral stricture: How to optimise the use of buccal mucosal grafts



Jonathan N. Warner <sup>a,\*</sup>, Eric S. Wisenbaugh <sup>b</sup>, Francisco E. Martins <sup>c</sup>

<sup>a</sup> City of Hope Medical Center, Duarte, CA, USA

<sup>b</sup> University of California, Irvine, CA, USA

<sup>c</sup> Department of Urology, University of Lisbon School of Medicine, Santa Maria Hospital, Lisbon, Portugal

Received 29 September 2015, Received in revised form 5 January 2016, Accepted 12 January 2016

Available online 19 February 2016

## KEYWORDS

Urethral stricture;  
Bulbar mucosal urethroplasty;  
Anastomotic urethroplasty

## ABBREVIATIONS

AU, anastomotic urethroplasty;  
BMG(U), buccal mucosa graft (urethroplasty);  
ED, erectile dysfunction

**Abstract** The use of buccal mucosa graft urethroplasty (BMGU) for bulbar urethral strictures has gained widespread popularity since the first report in 1996. Over the last two decades, there have been many modifications in the surgical technique. This, along with better understanding of urethral anatomy, has allowed the BMG to become the ‘gold standard’ in urethral substitution. The present article reviews the evolution and techniques of BMGU in order to answer the question – how do we optimise the use of BMGs?

© 2016 Arab Association of Urology. Production and hosting by Elsevier B.V. This is an open access article under the CC BY-NC-ND license (<http://creativecommons.org/licenses/by-nc-nd/4.0/>).

## Introduction

Bulbar urethral strictures require comprehensive and careful urological management. Generally speaking, urethroplasty is the preferred treatment method, conferring far superior and more durable urethral patency rates compared with urethral incision or dilatation [1,2]. Buccal mucosa has gained widespread popularity as the graft of choice for bulbar urethroplasty.

\* Corresponding author at: City of Hope Medical Center, Surgery, Division of Urology, 1500 East Duarte Rd., Duarte, CA 91010, USA. Tel.: +1 8016998975; fax: +1 6269143726.

E-mail address: [Jonathan.n.warner@gmail.com](mailto:Jonathan.n.warner@gmail.com) (J.N. Warner).  
Peer review under responsibility of Arab Association of Urology.



Production and hosting by Elsevier

Moreover, some authors prefer buccal mucosa graft urethroplasty (BMGU) to anastomotic urethroplasty (AU) as the treatment of choice for bulbar urethral strictures. The present article explores the history of BMGU along with various techniques. It also reviews why some others now prefer BMG to AU, and will answer the question: how do we optimise outcomes of BMGU?

## History

The first BMGU was reported by Sapezhko [3] in 1894, in a series of four cases. In 1941, the idea was re-explored by Humby [4] in the setting of hypospadias repair. El-Kasaby et al. [5] reported the use of mucosa from the lower lip, as a free graft, for the management of penile and bulbar urethral strictures in 1993. In 1996, two techniques were described using buccal mucosa for bulbar urethral strictures. Morey and McAninch [6] described a ventral onlay technique, whereas Barbagli et al. [7] described a dorsal onlay technique. Since that time, BMGU has been widely used in both one-stage and two-stage repairs. Additionally, modifications to the original techniques described above have minimised surgical trauma and improved outcomes.

## Why use BMGs?

Reported success rates of AU range from 90% to 99% in series with >100 patients and  $\geq 2$  years of follow-up [8–11]. The success rate of BMGU ranges from 85% to 95% [7,12–16]. While there have been some comparative analyses showing similar success rates between AU and BMGU [17], that has not been the case for most direct comparison between AU and BMGU [18,19]; however, these have been biased by the longer strictures treated with BMGU compared with AU.

Despite the possible higher failure rates with BMGU, many urologists have preferred this approach to AU for even short bulbar urethral strictures. This is primarily as a result of sexual side-effects seen after AU. For example, Morey and Kizer [20] examined a series of 11 patients with AU for strictures >2.5 cm long and found a 17% dissatisfaction rate and 33% of patients reporting a decreased penile length; for strictures of <2.5 cm (also 11 patients) they reported still more unfavourable outcomes with 44% dissatisfaction rate, 44% chordee rate, and 22% decreased penile length rate. Similarly, Barbagli et al. [10] described results of 153 cases of AU and found a 23% ejaculatory dysfunction rate, 12% cold or soft glans, and 20% decrease in sensitivity; they go on to emphasise that removing longer strictures risks penile shortening or chordee, even when lengthening manoeuvres are utilised.

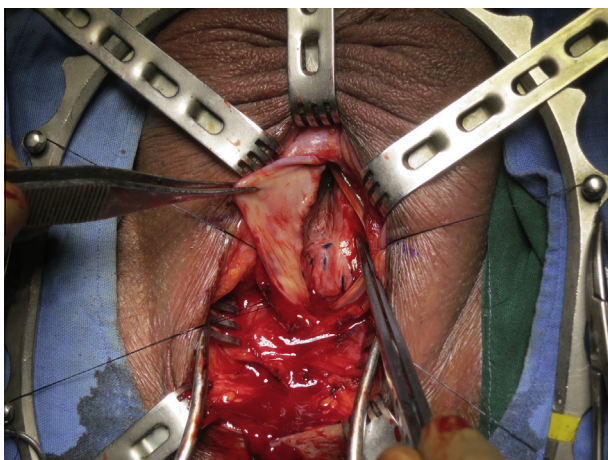
Many of the detriments found when using AU are not seen with the use of BMGU. For example, the reported rate of erectile dysfunction (ED) for BMGU

is very low. Some report no erectile dysfunction with BMGU [21,22], while others report a somewhat higher, yet still a favourable rate. For example, Coursey et al. [23] reported 19.2% patient-reported erectile dysfunction (ED) rates with BMGU compared with 26.8% reported ED after AU.

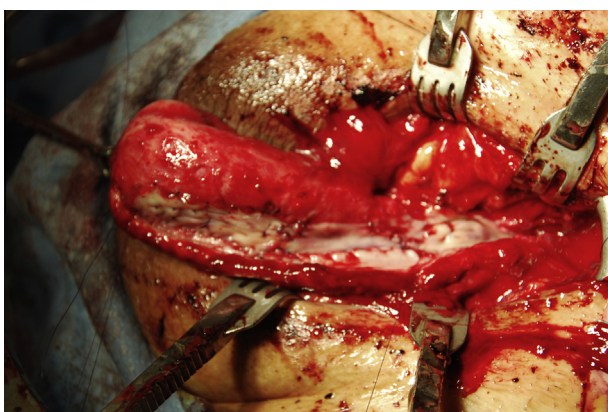
Another advantage of BMGU is its effectiveness for longer strictures. While some authors approach longer strictures with AU [20], historically stricture length appropriate for AU use was limited to 1–3 cm. Some authors even reserve AU for  $\leq 1$  cm strictures and use an augmented AU for strictures of >1 cm [24]. Allowing for excision of the entire scar, and 1 cm spatulation on either side, the range of bulbar urethral utilisation is 3–5 cm, even for 1-cm strictures. Therefore, longer strictures that require distal mobilisation of the bulbar urethra are more prone to incorporate the penile urethra, and more likely to induce postoperative chordee. For longer strictures, some authors then advocate an augmented AU, which will allow an additional 1–2 cm of length, while still allowing the dense scar to be excised [24]. Outcomes have been favourable with this approach with success rates of 90% [25]. Meanwhile, only the length of the graft that can be obtained limits BMGU. A small 1-cm stricture can be managed with a 3-cm graft, without mobilisation. A large 6-cm stricture extending into the penile urethra can be managed with a dorsal onlay buccal graft with a one-sided, muscle and nerve preserving approach as described by Barbagli et al. [26]. This is just one example of the various approaches and modifications that have been developed for BMGU, which will be explored below.

## The various approaches to BMGU

BMGU offers a wide array of surgical approaches, thereby offering many options for stricture management to be tailored to surgeon preference. Since the initial dorsal and ventral reports in 1996 [6,7], several modifications of BMGU have been described. It should be noted that comparative reports have described similar outcomes with the dorsal vs ventral onlay approach [27]. Given the robust nature of the ventral spongiosum in the proximal bulbar urethra, a ventral approach offers more simplicity and does not necessitate the dissection of the lateral circumflex vessels. Fig. 1 depicts a ventral onlay buccal mucosal urethroplasty. In the distal bulb and the penile urethra, the ventral spongiosum is not robust enough to support the ventral onlay approach, and therefore a dorsal approach should be used if the stricture extends beyond the proximal bulb. Fig. 2 depicts the dorsal onlay approach for a pan-urethral stricture. Some surgeons use the distal edge of the bulbospongiosus muscle as the extent to which a ventral graft should be used. Wessells [28] reported the advantages of the ventral approach including: preserva-



**Figure 1** Ventral onlay BMGU.



**Figure 2** Dorsal onlay BMGU for a pan-urethral stricture.

tion of the lateral blood supply between the spongiosum and corpora, as there is no need to fully mobilise the urethra circumferentially, the lumen of the stricture is easily visualised allowing the water-tight anastomosis to be easily made, and a portion of the stricture can be excised if needed and a dorsal re-anastomosis can be performed.

Despite the surgical ease and the above advantages of the ventral approach, some surgeons prefer the dorsal approach for several reasons. This approach allows better control and visualisation because blood loss is minimised given the shallow nature of the spongiosum dorsally. It also is not dependent on a healthy spongiosum and so should be resistant to spongiofibrosis. Additionally, it allows for spread-fixation of the graft to a firm graft bed of corpora, which may in theory prevent it from contracting or folding as it heals and provide a wider long-term urethral patency. As mentioned previously, if the stricture involves the distal bulb or the penile urethra, then most agree that a dorsal approach should be used. In the dorsal approach, it is necessary to mobilise the urethra off of the corpora, thereby dividing the corporal and spongiosal attachments and vascu-

lature. Mangera et al. [16] performed a large systematic review of various approaches, which revealed similar outcomes between dorsal and ventral onlay urethroplasties.

Barbagli et al. [26] have described several key steps to minimise the trauma to the lateral neurovascular supply to the urethra while still offering an effective repair. With his technique, only a small amount of the bulbospongiosus muscle is divided, and the majority is lifted off of the spongiosum and retracted posteriorly. In addition, using a one-sided dissection to lift the urethra off of the corpora, preserves half of the circumflex vessels from the contralateral side of the urethra [29]. This approach can be used to repair the entire urethra through a penile inversion technique, as described by Kulkarni et al. [30].

One technique that combines some of the principles from both the dorsal and ventral approaches is a technique that was proposed in 2001 by Asopa et al. [31]. The authors described an inlay approach to the management of strictures for penile and bulbar urethral strictures. In this approach, the ventral urethra is incised, exposing the dorsal urethral plate. The dorsal plate is incised longitudinally and splayed open and a BMG is placed into the exposed tunica albuginea [31]. The largest series using BMG was described by Pisapati et al. [32], with an 87% success rate at 42 months follow-up.

Finally, a double-faced graft has been described by several authors, where a ventral and a dorsal inlay are placed simultaneously. Palminteri et al. [33] described the increased success of this approach for narrow-lumen urethral strictures compared with a single-sided graft, and Chen et al. [34], using a combination skin and BMG, reported a higher success rate for longer strictures using two grafts vs one graft (> 6 cm). Similarly, Gelman and Siegel [35] described a similar approach in 18 patients, with success noted in 17 of 18 patients.

While there is disagreement on the ideal procedure, all of the above described techniques have been described with excellent outcomes, which are far superior to any endoscopic technique, the above procedures report excellent outcomes as summarised in [Table 1](#).

### Graft dissection and securing the BMG

Any discussion on optimising a BMG would be incomplete without the discussion of the graft harvest. Labial (lip) mucosa tends to be thinner and yields a narrower plate compared with that of the buccal mucosa of the inner cheek [38]; however, it offers a viable graft when the inner cheek is not accessible. Lingual grafts have also been used and offer similar outcomes to those of grafts from the cheek [39]. Barbagli et al. [40] reported on the complications of the oral graft site, in a series of ovoid grafts with site closure and noted graft site

**Table 1** Summary of published reports.

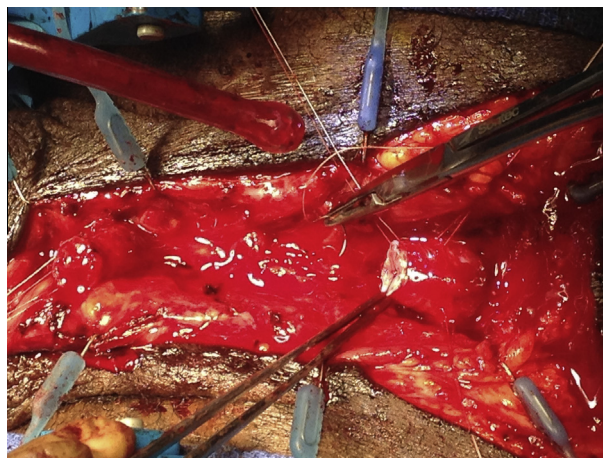
Reference	Approach	Patients, <i>n</i>	Success, %	Mean follow-up, months
Eltahawy et al. [11]	AU	260	98.8	50.2
Santucci et al. [9]	AU	168	95.2	72
Barbagli et al. [8]	AU	165	90.9	64
Mangera et al. [16]	Dorsal onlay	934	88	42
	Ventral onlay	563	88	34
Barbagli et al. [36]	Lateral onlay	6	83	160
	Augmented anastomotic repair with BMG	24	75	113
Pisapati et al. [32]	Asopa inlay with buccal mucosa	45	87	42
Palminteri et al. [33]	Two sided with buccal mucosa	166	90	47
Guralnick and Webster [24]	Augmented AU flaps and grafts	29	93	28
Abouassaly and Angermeier [25]	Augmented AU with buccal mucosa	69	90	34
Kulkarni et al. [37]	Dorsal onlay buccal graft for pan-urethral stricture	117	84	59

bleeding in 4.3%, mild pain in 15%, numbness for 1 week in 73.4%, which persisted in 3.7% at 3 months. There has been some debate as to whether the graft site should be closed or left open. Rourke et al. [41] performed a randomised trial comparing the outcomes of leaving the graft site open or closed. They found no difference in the pain scores at day 3 (although there was a trend favouring the open group) and 6 months; however, leaving the site open had a lower rate of numbness, earlier rate of return to regular diet, and normal mouth opening compared with the closed graft bed group [41]. Others still argue that the graft shape and location should be the determining factor as to when to leave the site open and when the site should be closed [42].

Once the graft is harvested, the next step is to remove all fat and muscle from the graft. Finally, the graft needs to be secured to the supportive base. Some advocate fibrin glue to achieve this for the dorsal onlay approach [29], while others use quilting as the means to attach the graft [37]. When the graft is on the dorsal side, the use of fenestration has been described [38], no comparative analysis has been performed to determine if it makes a difference in success rates. Ventral onlay urethroplasty depends on securing the graft to the overlying spongiosum. While some prefer to simply let the spongiosum lay over the top, only securing the outer fascial layer of the spongiosum [6], others are more precise in securing the spongiosum directly to the graft [43]. It seems logical that securing the sponge directly to the graft is going to ensure an appropriate vascular bed, and as long as the securing sutures are precise and delicate through the spongiosal tissue, there will be no compromise to the blood supply.

#### When not to use BMGs

Despite the above advantages and versatility that buccal mucosa offers, there is one clear instance when a BMG cannot be used – trauma associated with complete disruption or significant spongiosal scarring. In this scenario an AU is the preferred method of repair, as seen

**Figure 3** An AU.

in Fig. 3. A study evaluating the causes of urethral strictures found that of 732 patients, the cause was 33% idiopathic, 33% iatrogenic, 15% inflammatory, and 19% traumatic [44]. Trauma-induced strictures are often associated with spongiosal scarring, which makes grafting unacceptable. Furthermore, the urethra can become entirely occluded and thereby creating a section without a urethral plate. Fortunately, these strictures are often short, and can be easily repaired via a small perineal incision. When an obliterated stricture is > 2 cm, the preferred repair is an augmented anastomotic repair or the combination of ventral/dorsal graft described above for even longer strictures [45,46]. Interestingly, while expert opinion suggests that even for non-occlusive traumatic urethral strictures AU should be performed [47], several long-term reports of substitution urethroplasty citing trauma as a cause had similar failure rates to those strictures due to other causes [36,48]. It is likely that, although these strictures were classified as trauma, they were not likely severe occlusive trauma with significant spongiosal scarring. Some authors argue that one cannot possibly know the true cause of an idiopathic stricture [49]. Many of these may have been

a forgotten childhood perineal trauma that did not result in significant immediate complications, but rather a delayed presentation. What the reports indicate is that the trauma-induced strictures not associated with occlusion or significant spongiosal scarring can be treated with BMGU. An additional scenario when one might be inclined to perform an AU over a BMGU, is in patients with pre-existing ED. Here, the added advantage of superior long-term outcomes may prompt urologists to select the AU over BMGU.

One final issue to address is the use of flaps. Although the wide spread use of BMGU has led to a decline in the use of flaps, the role of flaps cannot be ignored. Flaps have been shown to have similar success rates as BMGU and AU in a recent series, although with more complications [50]. Flaps offer the advantage of allowing a tubular segment to be restored, which may be necessary in severe mid-urethral stenosis or obliteration, or as may occur in bulbar urethral necrosis [51]. Others will prefer to use flaps over grafts in the penile urethra in the setting of a narrow urethral plate.

## Conclusion

Optimisation of BMGU includes the appropriate selection of technique, appropriate handling of tissue, and appropriate use of graft fixation. The BMG provides an optimal substitution material for urethral reconstruction given its versatility and robust nature. While considerable debate still exists as to which technique is ideal for a certain stricture, all of the techniques described using buccal mucosa have excellent outcomes with low morbidity.

## Conflicts of interest

None declared.

## Source of funding

None.

## References

- [1] Chapple C, Andrich D, Atala A, Barbagli G, Cavalcanti A, Kulkarni S, et al. SIU/ICUD consultation on urethral strictures: the management of anterior urethral stricture disease using substitution urethroplasty. *Urology* 2014;**83**(Suppl.):S31–47.
- [2] Morey AF, Watkin N, Shenfeld O, Eltahawy E, Giudice C. SIU/ICUD consultation on urethral strictures: anterior urethra-primary anastomosis. *Urology* 2014;**83**(Suppl.):S23–6.
- [3] Sapezhko KM. To the treatment of urethral defects using mucosa grafts (in Russian). *Chirurgicheskaya Letopis* 1894;**4**:775–84.
- [4] Humby G. One-stage operation for hypospadias. *Br J Surg* 1941;**29**:84–92.
- [5] El-Kasaby AW, Fath-Alla M, Noweir AM, El-Halaby MR, Zakaria W, El-Beialy MH. The use of buccal mucosa patch graft in the management of anterior urethral strictures. *J Urol* 1993;**149**:276–8.
- [6] Morey AF, McAninch JW. When and how to use buccal mucosal grafts in adult bulbar urethroplasty. *Urology* 1996;**48**:194–8.
- [7] Barbagli G, Selli C, Tosto A, Palminteri E. Dorsal free graft urethroplasty. *J Urol* 1996;**155**:123–6.
- [8] Barbagli G, Guazzoni G, Lazzeri M. One-stage bulbar urethroplasty: retrospective analysis of the results in 375 patients. *Eur Urol* 2008;**53**:828–33.
- [9] Santucci RA, Mario LA, McAninch JW. Anastomotic urethroplasty for bulbar urethral stricture: analysis of 168 patients. *J Urol* 2002;**167**:1715–9.
- [10] Barbagli G, De Angelis M, Romano G, Lazzeri M. Long-term followup of bulbar end-to-end anastomosis: a retrospective analysis of 153 patients in a single center experience. *J Urol* 2007;**178**:2470–3.
- [11] Eltahawy EA, Virasoro R, Schlossberg SM, McCammon KA, Jordan GH. Long-term followup for excision and primary anastomosis for anterior urethral strictures. *J Urol* 2007;**177**:1803–6.
- [12] Barbagli G, Selli C, di Cello V, Mottola A. A one-stage dorsal free-graft urethroplasty for bulbar urethral strictures. *Br J Urol* 1996;**78**:929–32.
- [13] Andrich DE, Leach CJ, Mundy AR. The Barbagli procedure gives the best results for patch urethroplasty of the bulbar urethra. *BJU Int* 2001;**88**:385–9.
- [14] Iselin CE, Webster GD. Dorsal onlay graft urethroplasty for repair of bulbar urethral stricture. *J Urol* 1999;**161**:815–8.
- [15] Kane CJ, Tarman GJ, Summerton DJ, Buchmann CE, Ward JF, O'Reilly KJ, et al. Multi-institutional experience with buccal mucosa onlay urethroplasty for bulbar urethral reconstruction. *J Urol* 2002;**167**:1314–7.
- [16] Magera A, Patterson JM, Chapple CR. A systematic review of graft augmentation urethroplasty techniques for the treatment of anterior urethral strictures. *Eur Urol* 2011;**59**:797–814.
- [17] Chen ML, Odom BD, Santucci RA. Substitution urethroplasty is as successful as anastomotic urethroplasty for short bulbar strictures. *Can J Urol* 2014;**21**:7565–9.
- [18] Andrich DE, Dungalison N, Greenwell TJ, Mundy AR. The long-term results of urethroplasty. *J Urol* 2003;**170**:90–2.
- [19] Barbagli G, Palminteri E, Bartoletti R, Selli C, Rizzo M. Long-term results of anterior and posterior urethroplasty with actuarial evaluation of the success rates. *J Urol* 1997;**158**:1380–2.
- [20] Morey AF, Kizer WS. Proximal bulbar urethroplasty via extended anastomotic approach – what are the limits? *J Urol* 2006;**175**:2145–9.
- [21] Fransis K, Vander Eeckt K, Van Poppel H, Joniau S. Results of buccal mucosa grafts for repairing long bulbar urethral strictures. *BJU Int* 2010;**105**:1170–2.
- [22] Al-Qudah HS, Santucci RA. Extended complications of urethroplasty. *Int Braz J Urol* 2005;**31**:315–25.
- [23] Coursey JW, Morey AF, McAninch JW, Summerton DJ, Secrest P, White P, et al. Erectile function after anterior urethroplasty. *J Urol* 2001;**166**:2273–6.
- [24] Guralnick ML, Webster GD. The augmented anastomotic urethroplasty: indications and outcome in 29 patients. *J Urol* 2001;**165**:1496–501.
- [25] Abouassaly R, Angermeier KW. Augmented anastomotic urethroplasty. *J Urol* 2007;**177**:2211–6.
- [26] Barbagli G, De Stefani S, Annino F, De Carne C, Bianchi G. Muscle- and nerve-sparing bulbar urethroplasty: a new technique. *Eur Urol* 2008;**54**:335–43.
- [27] Barbagli G, Palminteri E, Guazzoni G, Montorsi F, Turini D, Lazzeri M. Bulbar urethroplasty using buccal mucosa grafts placed on the ventral, dorsal or lateral surface of the urethra: are results affected by the surgical technique? *J Urol* 2005;**174**:955–8.
- [28] Wessells H. Ventral onlay graft techniques for urethroplasty. *Urol Clin North Am* 2002;**29**:381–7.

- [29] Barbagli G, De Stefani S, Sighinolfi MC, Annino F, Micali S, Bianchi G. Bulbar urethroplasty with dorsal onlay buccal mucosal graft and fibrin glue. *Eur Urol* 2006;**50**:467–74.
- [30] Kulkarni S, Barbagli G, Sansalone S, Lazzeri M. One-sided anterior urethroplasty: a new dorsal onlay graft technique. *BJU Int* 2009;**104**:1150–5.
- [31] Asopa HS, Garg M, Singhal GG, Singh L, Asopa J, Nischal A. Dorsal free graft urethroplasty for urethral stricture by ventral sagittal urethrotomy approach. *Urology* 2001;**58**:657–9.
- [32] Pisapati VL, Paturi S, Bethu S, Jada S, Chilumu R, Devraj R, et al. Dorsal buccal mucosal graft urethroplasty for anterior urethral stricture by Asopa technique. *Eur Urol* 2009;**56**:201–5.
- [33] Palminteri E, Lumen N, Berdondini E, Di Pierro GB, Cucchiara G, Tenti G, et al. Two-sided dorsal plus ventral oral graft bulbar urethroplasty: long-term results and predictive factors. *Urology* 2015;**85**:942–7.
- [34] Chen ML, Odom BD, Johnson LJ, Santucci RA. Combining ventral buccal mucosal graft onlay and dorsal full thickness skin graft inlay decreases failure rates in long bulbar strictures ( $\geq 6$  cm). *Urology* 2013;**81**:899–902.
- [35] Gelman J, Siegel JA. Ventral and dorsal buccal grafting for 1-stage repair of complex anterior urethral strictures. *Urology* 2014;**83**:1418–22.
- [36] Barbagli G, Kulkarni SB, Fossati N, Larcher A, Sansalone S, Guazzoni G, et al. Long-term followup and deterioration rate of anterior substitution urethroplasty. *J Urol* 2014;**192**:808–13.
- [37] Kulkarni SB, Joshi PM, Venkatesan K. Management of panurethral stricture disease in India. *J Urol* 2012;**188**:824–30.
- [38] Barbagli G, Palminteri E, Guazzoni G, Cavalcanti A. Bulbar urethroplasty using the dorsal approach: current techniques. *Int Braz J Urol* 2003;**29**:155–61.
- [39] Abdelhameed H, Elgamal S, Farha MA, El-Abd A, Tawfik A, Soliman M. The long-term results of lingual mucosal grafts for repairing long anterior urethral strictures. *Arab J Urol* 2015;**13**:128–33.
- [40] Barbagli G, Vallasciani S, Romano G, Fabbri F, Guazzoni G, Lazzeri M. Morbidity of oral mucosa graft harvesting from a single cheek. *Eur Urol* 2010;**58**:33–41.
- [41] Rourke K, McKinny S, St Martin B. Effect of wound closure on buccal mucosal graft harvest site morbidity: results of a randomized prospective trial. *Urology* 2012;**79**:443–7.
- [42] Barbagli G, Lazzeri M, Rourke et al.: effect of wound closure on buccal mucosal graft harvest site morbidity: results of a randomized prospective trial (urology 2012;79:443–448). *Urology* 2012;**80**:741–2.
- [43] Barbagli G, Montorsi F, Guazzoni G, Larcher A, Fossati N, Sansalone S, et al. Ventral oral mucosal onlay graft urethroplasty in nontraumatic bulbar urethral strictures: surgical technique and multivariable analysis of results in 214 patients. *Eur Urol* 2013;**64**:440–7.
- [44] Fenton AS, Morey AF, Aviles R, Garcia CR. Anterior urethral strictures: etiology and characteristics. *Urology* 2005;**65**:1055–8.
- [45] Barbagli G, Palminteri E, Lazzeri M, Guazzoni G. Anterior urethral strictures. *BJU Int* 2003;**92**:497–505.
- [46] Peterson AC, Webster GD. Management of urethral stricture disease: developing options for surgical intervention. *BJU Int* 2004;**94**:971–6.
- [47] Barbagli G, Sansalone S. Oral mucosal graft urethroplasty. In: Brandes SB, Morey AF, editors. *Advanced male urethral and genital reconstructive surgery*. second ed. New York: Humana Press; 2014. p. 177–95.
- [48] Warner JN, Santucci RA. The management of the acute setting of pelvic fracture urethral injury (realignment vs. suprapubic cystostomy alone). *Arab J Urol* 2015;**13**:7–12.
- [49] Morey AF. Re: ventral oral mucosal onlay graft urethroplasty in nontraumatic bulbar urethral strictures: surgical technique and multivariable analysis of results in 214 patients. *J Urol* 2014;**191**:694–5.
- [50] Warner JN, Malkawi I, Dhradkeh M, Joshi PM, Kulkarni SB, Lazzeri M, et al. A multi-institutional evaluation of the management and outcomes of long-segment urethral strictures. *Urology* 2015;**85**:1483–7.
- [51] Kulkarni SB, Joshi PM, Hunter C, Surana S, Shahrour W, Alhajerji F. Complex posterior urethral injury. *Arab J Urol* 2015;**13**:43–52.