



Effect of Ethanolic Extracts of Lemon Grass and Mango Bark on the Cerebral Astrocytes of Adult Wistar Rats

**M. A. Eluwa^{1*}, E. I. Ngwu¹, O. R. Asuquo¹, A. O. Akpantah¹,
T. E. Isamoh¹ and T. B. Ekanem¹**

¹*Department of Anatomy, Faculty of Basic Medical Sciences, University of Calabar, Cross River State, Nigeria.*

Authors' contributions

This work was carried out in collaboration between all authors. Authors MAE, EIN and ORA designed the study, performed the statistical analysis, wrote the protocol, and wrote the first draft of the manuscript. Authors AOA and TEI managed the analyses of the study. Author TBE managed the literature searches. All authors read and approved the final manuscript.

Original Research Article

Received 3rd June 2014
Accepted 4th July 2014
Published 8th August 2014

ABSTRACT

Aims: Lemon grass and mango bark serves as one of the medicinal plants used in Nigeria for the treatment of malaria by traditional herbalists. This study was designed to assess the effects of ethanolic extract of lemon grass and mango bark on the cerebral astrocytes of wistar rats.

Place and Duration of Study: Department of Human Anatomy, Faculty of Basic Medical Sciences, University of Calabar, Calabar, Nigeria between December 2013 and May 2014.

Methodology: Twenty (20) adult wistar rat were divided into four groups, each consisting of five rats. Group A served as the control that received distilled water, while the experimental groups B, C and D received 2000mg/kg ethanolic extract of lemon grass, 2000mg/kg ethanolic extract of mango bark, a combination of 1000mg/kg ethanolic extract of lemon grass and 1000mg/kg ethanolic extract of mango bark orally with the aid of orogastric tube respectively for two weeks and were sacrificed using chloroform. The brain of the rats were harvested and preserved using 10% formal saline. Histological processes were carried out and the tissues were stained using Hortegas.

*Corresponding author: Email: mokamaeluwa@yahoo.com;

Results: Neurohistological studies carried out revealed hyperplasia of astrocytes in the treated groups B, C and D animals that received 2000mg/kg of ethanolic extract of lemon grass, 2000mg/kg of mango bark and combined 1000mg/kg of ethanolic extract of lemon grass and 1000mg/kg of ethanolic extract of mango bark. There was increased hyperplasia in group B animals that received 2000mg/kg of the lemon grass extract when compared with the control and the treated groups C and D.

Conclusion: Thus, ethanolic extract of lemon grass, mango bark and combined extracts of mango bark and lemon grass has the potential to cause neuronal damage as seen in the hyperplasia of cerebral cortex astrocytes.

Keywords: Lemon grass; mango bark; cerebral cortex; astrocytes; neurohistology.

1. INTRODUCTION

Herbal medicine or herbalism makes use of the medicinal properties of plant. The scope of herbal medicine is extended to include fungal and other product as well as minerals, shells and certain animal parts and products. Plants have the ability to synthesize a wide variety of chemical compounds that are used to defend against attack from predators such as insects, fungi and herbivorous mammals. Many of these phytochemical components of plant have beneficial effects on long-term health when consumed by humans and can be used to effectively treat human diseases [1].

Lemon grass and mango bark are among the large spectrum of herbs used in treatment of many diseases. Every part of the mango trees (roots, stem, bark, seeds), all have curative and medicinal properties. Mango bark is also well known for its medicinal properties as it is an astringent, acrid, refrigerant, styptic and has anti-emetic, anti-inflammatory and constipating properties [2]. Mango bark has medicinal properties as it is used traditionally for curing constipation, calorrhagia, pneumonia, syphilis, uteritis, wounds, ulcers and vomiting. The juice of fresh mango bark has a marked action on mucous membranes in menorrhoea, leucorrhoea, bleeding, piles and diarrhoea. An ointment of resinous bark gum of tree bark had been described in dressing scabies and other parasitic skin diseases [2]. The anti-plasmodial and antipyretic effect of mango bark has also been demonstrated [3] which makes mango bark very useful in the treatment of malaria.

Lemon grass is used in the treatment of fever, gastro intestinal disorder, diarrhoea, vomiting, neuroglia and etc [4]. Studies have shown that lemon grass also has antibacterial activity comparable to penicillin [5]. It is used to treat stomach ache, headaches, and flu. It is helpful in treating muscular pain, poor circulation, muscle tone and slack tissue. The antiseptic oil treats athletic food and acne [6].

Astrocytes are neuroglia which play supporting and metabolic role and they also act as macrophages within the nervous system [7]. They are star shaped and are made up of two forms: the fibrous astrocytes and protoplasmic astrocyte. The fibrous astrocytes are related to the white matter having small cell bodies with long processes and protoplasmic astrocytes have more processes than those seen in the fibrous astrocytes. These astrocytes contain multiple of small-round-dark glycogen granules that make astrocytes appear dark when stained [8,9]. There is no evidence in literature to show the effect of lemon grass, mango bark and combined intake of the lemon grass and mango bark on the reactive astrocytes in

the cerebral cortex of wistar rats. Thus, this research was carried out to investigate the effect of the ethanolic extracts of these plants on the cerebral astrocytes.

2. MATERIALS AND METHODS

After acclimatization, adult Wistar rats (animal house, Department of Animal Science, University of Calabar), were housed in a pathogen-free facilities on a 12-hour light/dark schedule, were randomly divided into four groups (five each). The animals were feed with growers mash obtained from vital food company at no. 2 Mount Zion Street, Calabar and water was provided *ad libitum*. Their beddings were changed daily to keep the rats immediate environment clean and uncontaminated.

2.1 Herbal Preparation

The herbs (lemon grass and mango bark) were collected from a botanical garden in Akpabuyo Local Government Area of Calabar, Cross River State. The herbs were authenticated and confirmed by the botanist in the botanical garden of the University of Calabar. The lemon grass leaves were washed in water to remove impurities and sun dried. The mango barks were chopped into small pieces to facilitate the drying process under the sun. The lemongrass and the mango bark were grinded to powder separately using electric blender in New Chemistry Laboratory, Department of Chemistry, University of Calabar. The lemon grass and the mango bark powder were also soaked in 2 liters of ethanol for 72 hours. The suspensions were filtered using 150mm size Whatmann filter paper. The precipitates were allowed for evaporation to dryness at room temperature leaving a crude extract.

2.2 Experimental Protocol

Twenty adult Wistar rats were randomly divided into four groups (five each). Group A, considered as control, groups B, C and D were considered as treated groups that received plant extracts. The ethanolic extract of lemon grass and mango bark were administered orally by orogastric tube to the animals in the experimental groups respectively for a period of two weeks.

2.3 Extract Administration

Group A- Animals were feed with rat chow and distilled water.

Group B- Animals received 2000mg/kg of ethanolic extract of lemon grass for 2 weeks.

Group C- Animals received 2000mg/kg of ethanolic extract of mango bark for 2 weeks.

Group D- Animals received combine 1000mg/kg of the ethanolic, extracts of lemongrass and 1000mg/kg of the ethanolic extract of mango bark for 2 weeks.

2.4 Termination of Experiment

The animals were sacrificed 24 hours after the last administration using chloroform inhalation method. The brain was extracted; the cerebral cortex excised and preserved using 10% formal saline. Routine histological process was carried out. The cerebral cortex sections were stained for reactive astrocyte using Hortegas lithium carbonate method.

3. RESULTS AND DISCUSSION

3.1 RESULTS

In this study, the cerebral cortex of control group showed normal distribution of astrocytes stained black (plate. 1a). Sections of cerebral cortex from group B animals that received 2000mg/kg of ethanolic extract of lemon grass showed increased hyperplasia of astrocyte when compared with the control (plate 1b). Sections of cerebral cortex from group C animals that received 2000mg/kg of mango bark showed hyperplasia of astrocytes when compared with the control (plate 1c). Sections of cerebral cortex of group D animals that received combine 1000mg/kg of ethanolic extracts of lemon grass and mango bark 1000mg/kg, showed hyperplasia of astrocytes when compared with the control (plate 1d). Data showed hyperplasia in treated groups B, C and D. Hyperplasia in group B was significantly more than in groups C and D.

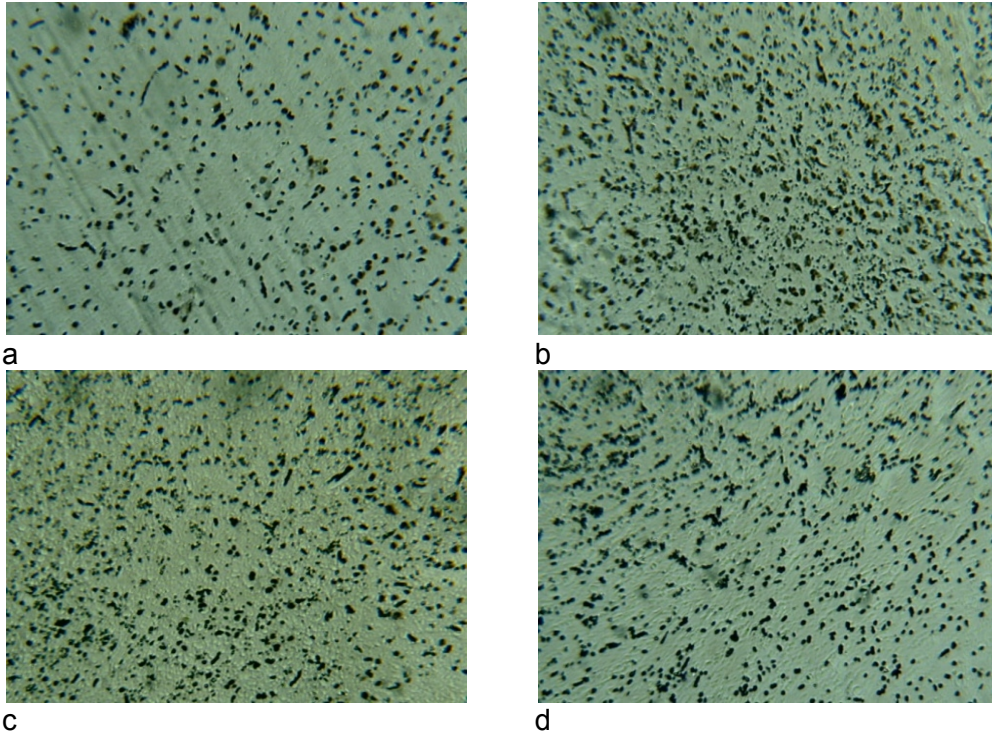


Plate 1. Photomicrographs of cerebral cortex of control and experimental groups (Hortega's lithium carbonate stain. Magx100); a) Cerebral cortex of control showing protoplasmic astrocyte stained black. b) Cerebral cortex-2000mg/kg of ethanolic extract of lemon grass showing increased hyperplasia of astrocytes compared with the control. c) Cerebral cortex-2000mg/kg of ethanolic extract of mango bark showing increased hyperplasia of astrocytes compared with the control. d) Cerebral cortex-combined 1000mg/kg of ethanolic extract of lemon grass and 1000mg/kg of ethanolic extract of mango bark showing hyperplasia of astrocytes

3.2 DISCUSSION

Astrocytes are neuroprotective, they are involved in healing and recovery of neurons in various system pathology and that in the central nervous injury, astrocytes act as neuroprotective sheath, they increase in number, filling injury zone, forming glial scar to fill defects left by loss of specialized nervous tissue [9]. Astrocytes, once relegated to a mere supportive role in the central nervous system, are now recognized as a heterogeneous class of cells with many important and diverse functions.

Major astrocyte functions can be grouped into three categories: guidance and support of neuronal migration during development, maintenance of the neural microenvironment, and modulation of immune reactions by serving as antigen-presenting cells. The concept of astrocytic heterogeneity is critical to understanding the functions and reactions of these cells in disease. Astrocytes from different regions of the brain have diverse biochemical characteristics and may respond in different ways to a variety of injuries. Astrocytic swelling and hypertrophy-hyperplasia are two common reactions to injury. This review covers the morphologic and pathophysiologic findings, time course, and determinants of these two responses. In addition to these common reactions, astrocytes may play a primary role in certain diseases, including epilepsy, neurological dysfunction in liver disease, neurodegenerative disorders such as Parkinson's and Huntington's diseases, and demyelination. Evidence supporting primary involvement of astrocytes in these diseases will be considered [10].

In this study, the effect of the ethanolic extract of lemon grass leaves, mango bark and combined extracts of lemon grass and mango bark on the cerebral astrocytes of adult wistar rats reveals that the control group A had a normal distribution of astrocytes while there was hyperplasia of astrocytes in the experimental groups B, C, and D animals that received 2000mg/kg of ethanolic extract of lemon grass leaves, 2000mg/kg of ethanolic extract of mango bark and a combined ethanolic extract of lemon grass and mango bark respectively when compared with the control. These neurohistological effects may have been due to some phytochemical constituents in the extracts of lemon grass and mango bark.

The result is in line with the work reported by Eluwa et al. [11] that the ethanolic extract of the herb *Sida acuta* though has medicinal properties is capable of causing cerebral tissue damage, evident by hypertrophy and hyperplasia of cerebral reactive astrocytes. A study carried out by Ekanem et al. [12] on the reactive astrocytes in the hippocampus of adult wistar rats after three day administration of antimalarial drugs mefloquine and artequine showed large, numerous and some few paired astrocytes. Also, Moses et al. [13] had reported hyperplasia and hypertrophy on Nissl substances and reactive astrocytes in the cerebellum of experimental groups treated with larimal. Fawcett et al. [14] documented that infections, trauma ischemia, stroke, auto immune response and other neurodegenerative diseases may cause increase in the number of reactive astrocyte in the central nervous system.

4. CONCLUSION

From the result of this work, it can be concluded that the ethanolic extract of lemon grass leaves, mango bark and combination of lemon grass and mango bark extracts may alter neuronal environment thus leading to cerebral cortex dysfunction competing interests Authors have declared that no competing interests exists in the course of this research.

CONSENT

Not applicable.

ETHICAL APPROVAL

All authors hereby declare that "Principles of laboratory animal care" (NIH publication No. 85-23, revised 1985) were followed, as well as specific national laws where applicable. All experiments have been examined and approved by the appropriate ethics committee.

COMPETING INTERESTS

Authors have declared that no competing interests exist.

REFERENCES

1. Tapsell LC, Hemphill L, Cobiac L, Patch CS, Sullivan DR, Feneeech M, et al. Health benefits of herbs and spices: The past, the present, the future. *Med J Aust.* 2006;185(4):4-24. PMID: 17022438.
2. Vijai K. Medicinal properties of mango (*Mangifera indica*). *Hortflora Res. Spectrum Current Issue.* 2013;2(4).
3. Awe SO, Olajide OA, Oladiran OO, Makinde JM. Antiplasmodial and antipyretic screening of *Mangifera indica* extract. *Phytother Res.* 1998;12(6):437-438. DOI: 10.1002/(SICI)1099-1573(199809)12:6.
4. Leite JR, Seabra ML, Maluf E, Assolant K, Suchecki D, Tufik S, et al. Pharmacology of lemongrass (*Cymbopogon citrates Stapf*) iii. Assessment of eventual toxic, hypnotic and anxiolytic effects on humans. *J Ethnopharmacol* 1986;17(1):75-83. PMID: 2429120.
5. Shadab Q, hanif M, Chaudhary FM. Antifungal activity of lemongrass essential oils. *Pak J Sci Ind Res.* 1992;35:246-249.
6. Sulaiman AAY. Antifungal activity of volatiles from lemongrass (*Cymbopogon citrates*) and peppermint (*Mentha piperita*) oils against some respiratory pathogenic species of *Aspergillus*. *Int J Curr Microbiol Appl Sci.* 2013;2(6):261-272. ISSN: 2319-7706.
7. Singh I. Introduction to Neuroanatomy. Text book Human Neuroanatomy. 6th ed Jaypee, New Delhi. 2002;22.
8. Lowe J, Cox G. Neuropathological techniques 3rd ed. Churchill Living Stone Edinburgh. 1992;79.
9. Peter RL, Eva S, Andreas E, Glenn IH, Herbert B. Glials cells: their roles in behavior. 1st ed. Cambridge University Press. 1998;315-332.
10. Montgomery DL. Astrocytes: Form, Function, and Role in Diseases. *Veterinary Pathology* 1994;31:145-169.
11. Eluwa MA, Mbah CO, Akpantah AO, Asuquo OR, Ekanem TB, Akpan EP, et al. Neurohistological study of the effect of ethanolic leaf extract of *Sida acuta* on the cerebral astrocytes of adult wistar rats. *Int J Pharma Sci Inv.* 2013;2(9):7-10.
12. Ekanem TB, Salami E, Ekong MB, Eluwa MA, Akpantah AO. Combination therapy antimalaria drugs mefloquine and Artequin induce Reactive Astrocytes formation in the Hippocampus of Rats. *The Int J Health.* 2009;9(2).
13. Ekong MB, Igiri AO, Mesembe OE, Salami E, Eluwa MA, Akpantah AO, et al. Effect of Larimal on Nissl substance and Reactive Astrocytes in the Cerebellum of Adult wistar Rats. *J Anat Sci.* 2009;(1):9-12.

14. Fawcett JW, Richard A, Asher E. The glial scar and central nervous system repair. *Brain Research Bulletin*. 1999;49(6):377-391.

© 2014 Eluwa et al.; This is an Open Access article distributed under the terms of the Creative Commons Attribution License (<http://creativecommons.org/licenses/by/3.0>), which permits unrestricted use, distribution, and reproduction in any medium, provided the original work is properly cited.

Peer-review history:

The peer review history for this paper can be accessed here:
<http://www.sciencedomain.org/review-history.php?iid=626&id=14&aid=5696>