

Phytochemical Screening and Hepatoprotective Potential of Aqueous Fruit Pulp Extract of *Adansonia digitata* against CCL₄ Induced Liver Damage in Rats

A. M. Sa'id^{1*}, A. H. Musa¹, J. A. Mashi¹, F. U. Maigari² and M. N. Nuhu³

¹Department of Biochemistry, Faculty of Basic Medical Sciences, Bayero University Kano, P.M.B 3011, Kano State, Nigeria.

²Department of Biochemistry, Faculty of Science, Gombe State University, P.M.B. 127, Gombe State, Nigeria.

³Department of Chemistry, Sa'adatu Rimi College of Education Kano, P.M.B. 3218, Kano State, Nigeria.

Authors' contributions

This work was carried out in collaboration among all authors. Author AMS designed the study, performed the statistical analysis, wrote the protocol and wrote the first draft of the manuscript. Authors AHM and JAM managed the analyses of the study. Authors FUM and MNN managed the literature searches. All authors read and approved the final manuscript.

Article Information

DOI: 10.9734/AJBGMB/2020/v3i3330086

Editor(s):

(1) Dr. Arulselvan Palanisamy, Muthayammal Centre for Advanced Research (MCAR), India.

(2) Dr. Mohammed Rachidi, University Paris Denis Diderot, France.

Reviewers:

(1) Che Norma Mat Taib, Universiti Putra Malaysia (UPM), Malaysia.

(2) G. Bupesh, Sree Balaji Medical College and Hospital, Bharath Institute of Higher Education and Research, India.

Complete Peer review History: <http://www.sdiarticle4.com/review-history/54697>

Original Research Article

Received 20 December 2019

Accepted 27 February 2020

Published 07 March 2020

ABSTRACT

Aim: The current study was carried out to evaluate the hepatoprotective effects of aqueous extract of *Adansonia digitata* fruit pulp on carbon tetrachloride (CCl₄) induced liver damage in rats.

Place and Duration of Study: Department of Biochemistry, Faculty of Basic Medical Sciences, College of Health Science, between November 2017 and January 2018.

Methodology: *A. digitata* fruit pulp was extracted by maceration using water; and a concentration of 100 mg/ml was used. Two doses of the aqueous extract (200 mg/kg and 300 mg/kg) and Livoline

*Corresponding author: E-mail: asmuhammad.bch@buk.edu.ng;

(25 mg/kg) were used to investigate their hepatoprotective effects on CCl₄-induced hepatotoxicity in rats.

Results: The two doses of the plant extract showed dose-dependent hepatoprotective effect on CCl₄-induced hepatotoxicity, as evident by the significant reduction (P<0.05) in serum levels of AST, ALT, ALP and bilirubin along with the improved histopathological liver sections compared to CCl₄-treated animals.

Conclusion: Due to its hepatoprotective potentials, *A. digitata* extract may be used to develop standard treatment drugs against some liver disorders when it is further evaluated through extensive researches.

Keywords: Liver; *Adansonia digitata*; carbon tetrachloride; hepatoprotective; histopathological.

1. INTRODUCTION

Biotransformation and clearance of xenobiotics from the body are the major roles played by the liver in maintaining homeostasis. Liver is a metabolically active organ that act as an important target of drugs and pathogens that may initiate liver cell damage and lead to the compromise its overall function [1]. Currently, there is no way to compensate for the absence of liver function in the long term and massive hepatic destruction often necessitates the need for liver transplantation [2]. There is therefore an intensive search of safe, affordable and readily available agents that can protect the liver from fulm inant damage [3]. Liver damage can be prevented by reducing the effect of reactive metabolites using antioxidants [4]. Natural polyphenolic compounds generally serve as liver protectants as they possess certain antioxidant and anti-inflammatory properties. Examples include resveratrol, quercetin, curcumin and silymarin [5-7].

Baobab (*Adansonia digitata*) is a large iconic tree indigenous to Africa where it is found in many countries. It is an emblematic, culturally important and physically majestic sub-tropical tree. The baobab has been referred to as "arbre a palabre", meaning the place in the village where the elders meet to resolve problems. In the past decade, it has attracted the interest of several pharmaceutical companies and researchers due to its various traditional uses (medicinal, nutritional and cosmetic). Recently, the European Commission authorized the import of baobab fruit pulp as a novel food [8] and it was approved in 2009 by the Food and Drug Administration as a food ingredient in the United State of America [9]. Due to the high demand for commercial baobab products in EU and United States, this tree with its edible fruits needs to be conserved and treasured [10,12]. Baobab products (e.g fruits, seeds, leaves and bark) contribute to the

livelihood of many populations in Africa as it is a source of food, fibre and medicine [13-16]. More than three hundred traditional uses have collectively been documented in Benin, Mali, Zimbabwe, Cameroon, the Central African Republic, Kenya, Malawi, South Africa and Senegal [8]. Various plant parts (e.g. leaves, bark, and fruit pulp), have traditionally been used for immune-stimulant, anti-inflammatory, analgesic, insect repellent and pesticidal properties, in the treatment of diarrhea and dysentery in many African countries, and have been evaluated as a substitute for imported western drugs [17,18].

Over the years, the number of patients with liver problem is increasingly alarming and the antihepatotoxic drugs discovered came with various side effects, as such there is a need for an alternative using natural resources (medicinal plants) that are less harmful to the body. These medicinal plants and herbs are often neglected and their medicinal values not deeply evaluated and with the threat of becoming extinct. The aim of this research work is therefore, to evaluate the effect of aqueous extract of *Adansonia digitata* fruit pulp on carbon tetrachloride (CCl₄) induced liver damage in rats.

2. MATERIAL AND METHODS

Carbon tetrachloride (CCl₄), olive oil, 10% formaline, 1% Ferric chloride solution, benzene, ammonium solution, acetic acid, conc. H₂SO₄, ethanol, acetic anhydride, 10% ferric chloride, 1% aqueous Hcl, dragendorff's reagent, Randox and Teco laboratory reagents. All materials and chemicals were of good grade and quality.

2.1 Collection of Plant Sample

The fruit pulp of *Adansonia digitata* was collected from within Kano metropolis. The plant was identified by Baha'uddeen Sa'id Adam, a plant

taxonomist in the Department of Biological Sciences, Bayero University, Kano. A herbarium accession number BUKHAN 0036 was deposited at the department's herbarium.

2.2 Preparation of Plant Extract

Exactly 200 g of dried fruit pulp of *Adansonia digitata* was added in 1000 ml of distilled water and kept at room temperature for 24 hours. Thereafter, the mixture was filtered using a white silky cloth and the filtrate transferred into a plastic bucket and subjected to evaporation in a water bath at 43°C, which last for 4 days before completely drying off and the residue was scrapped using a spatula. Soon after, 0.1 g of the residue was used to prepare the extract, diluted in 10 ml of distilled water (with concentration of 100 mg/ml).

2.3 Phytochemical Screening

The phytochemical screening was conducted according to the standard procedures described by Trease and Evans [19] and Sofowora [20]. The procedures for the phytochemical screening are shown below:

2.3.1 Test for tannin

About 2 ml of the filtrate was treated with few drops of 1% Ferric chloride solution. Formation of Blue-black, Green, Blue-green precipitate indicates a positive results.

2.3.2 Test for anthraquinones

About 2 ml portion of the filtrate was treated with 10 ml of benzene and was shaken, then 5 ml of 10% ammonium solution was added and shake again. The formation of rose pink coloration, Red, or violet color in the lower phase of the tube indicates a positive results.

2.3.3 Test for terpenoids

Small amount of the filtrate was treated with ethanol and 1 ml acetic anhydride was added to the solution followed by the addition of Conc.H₂SO₄. The formation or change of color, from pink to violet color indicates positive results.

2.3.4 Test for saponins

A fraction of the filtrate in a test tube was boiled by heating and then 3 ml of distilled water was added. The mixture was shaken vigorously for

5 min and it was observed for the formation of persistent foam that confirms the presence of saponin.

2.3.5 Test for flavonoids

2 ml of the extract was boiled and few drops of 10% Ferric chloride solution were added to the filtrate. Formation of green-blue or violet color indicates the presences of flavonoids.

2.3.6 Test for alkaloids

Small portion of the sample was treated with 5ml 1% Aqueous HCl, the mixture was stirred on a water bath followed by the addition of few drops of Dragendorff's reagent. The formation of orange-red precipitate indicates the presence of alkaloids.

2.4 Preparation of CCl₄ and Olive Oil

CCl₄ and olive oil were prepared in the ratio 1:1(30 ml of CCl₄ and 30 ml of olive oil, making 60ml). The preparation was kept in clean plastic bottle with tight cover.

2.5 Preparation of Livoline Drug

Three (3) capsules of livoline drug (each weighing 360 mg) were dissolved in 20 ml of distilled water for 8 hours.

2.6 Experimental Animals

Twenty-five (25) albino rats were purchased from Jos and allowed to acclimatize under the newly Kano environment for two (2) weeks in Biological Science Department. They were further divided into five cages according to their groups.

2.7 Experimental Design and Treatment

Twenty-five (25) male albino rats were divided into five groups of 5 rats each. Group 1 did not receive any dose of the extract neither did they receive any induction thus, serves as the positive control. Groups 2, 3, 4, and 5 were induced with hepatotoxicity using 2 ml/kg body weight of the prepared CCl₄ and olive oil (1:1 ratio mixture), where group 2 served as the negative control and groups 3, 4 and 5 served as the test groups. Groups 3 and 4 received a treatment with *A. digitata* extract on a dosage of 200 mg/kg and 300 mg/kg of body weight, while group 5 rats were treated with 200 mg/kg livoline (a standard drug) respectively for 7 days.

Twenty four hours after the last administration, blood collected from the animals by decapitation were put into sterile bottles and centrifuged at a rate of 12,000 revolutions per minute (rpm) for 10 mins. The clear serum obtained was analyzed for Aspartate transaminase (AST), Alanine transaminase (ALT), Alkaline phosphatase (ALP), Albumin, total protein and Bilirubin (total and direct).

2.8 Biochemical Analyses

Activities of serum AST, ALT and ALP were determined; and Albumin, total protein and Bilirubin (total and direct) concentrations were also determined using reagents and kits obtained from Randox Laboratories, UK.

2.8.1 Determination of serum AST and ALT

For serum AST and ALT estimation, reagent blank was prepared by mixing 0.5ml of reagent 1 with 0.1 ml of distilled water. While for serum samples, 0.1 ml of each sample was mixed with 0.5 ml of reagent. These mixtures were incubated for exactly 30 mins at 37°C, then 0.5 ml of reagent 2 was added to both the reagent blank and sample test tubes and allowed to stand for 20 mins at 23°C. Sodium hydroxide (5.0 ml) was added and mixed, then absorbance of the samples against the reagent blank was read after 5 minutes at 546 nm [21].

2.8.2 Determination of serum ALP

For each sample, 0.5 ml of alkaline phosphatase substrate was dispensed into labeled test tubes and equilibrated to 37°C for 3 minutes. At timed intervals, 0.05 ml of each standard, control, and sample were added to the labeled test tubes and mixed gently. Deionized water was used as sample for reagent blank. The mixtures were incubated for 10 minutes at 37°C and 2.5 ml alkaline phosphatase color developer was added to all test tubes and mixed carefully. Absorbance of the colored solutions was measured at 590 nm spectrophotometric ally [22].

2.8.3 Determination of total protein

In total protein determination, 0.02 ml each of distilled water, standard and serum was pipetted into labeled test tubes. Then 1.0 ml of reagent 1 was added to each of the labeled test tubes. The mixtures were incubated at for 30 minutes at 22°C. Absorbance of the sample was read against reagent blank at 550 nm [23].

2.8.4 Determination of albumin

For albumin estimation, 0.01 ml each of reagent, standard and sample was pipetted into labeled test tubes. Subsequently, 3.0 ml of BCG (bromocresol green) reagent 1 was added. The mixture was incubated for 5 minutes at 22°C. Absorbance of the sample was read against reagent blank at 630 nm [24].

2.8.5 Determination of serum bilirubin

For estimation of total bilirubin, 200 µl of reagent 1, 50 µl, 1000 µl and 200 µl of sample were mixed for each sample and allowed to stand for 20 mins at 22°C. Reagent 4 (1000 µl) was added to the mixture and allowed to stand at 23°C for 20 minutes. Absorbance of the sample was read at 578 nm against sample blank (ATB).

$$\text{Total bilirubin } (\mu\text{mol/l}) = 185 \times \text{ATB (578 nm)}$$

For direct bilirubin, 200 µl of reagent 1, 50 µl of reagent 2, 2000 µl of 0.9% NaCl and 200 µl were mixed in a cuvette and incubated at 22°C for 10 minutes. The absorbance of the sample was read at 546 nm against sample blank (ADB).

$$\text{Direct bilirubin } (\mu\text{mol/l}) = 246 \times \text{ADB (546 nm)}$$

$$\text{Unconjugated bilirubin} = \text{Total bilirubin} - \text{Direct bilirubin [25].}$$

2.9 Histopathological Analysis

The biopsy of the liver of the rats were fixed with 10% formal saline, dehydrated with ascending grade of alcohol cleared with toluene, infiltrated with molten paraffin wax. The microtome sections (5 µm-thick) were stained with haematoxylin and eosin staining technique [26].

2.10 Statistical Analysis

The results obtained were statistically analyzed by one-way ANOVA followed by Benforoni selected comparisons, using graph pad instat software. P value < 0.05 was considered significant.

3. RESULTS AND DISCUSSION

3.1 Results

The result of the phytochemical analysis is presented in Table 1 where all the constituents screened were present except anthraquinones which are absent.

Table 1. Phytochemical constituents of *A. digitata* fruit pulp

Phytochemical constituents	Result
Alkaloids	+
Flavonoids	+
Saponins	+
Tannins	+
Glycosides	+
Anthraquinones	-
Terpenes	+

+ indicates presence; - indicates absence

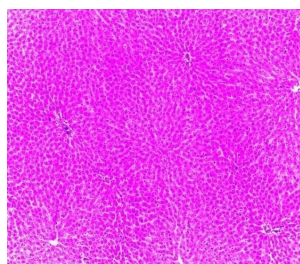


Fig. 1. (Group 1): Section shows unremarkable liver biopsy (H&E, mag ×100). It shows a normal hepatocyte architecture without any sign of liver damage

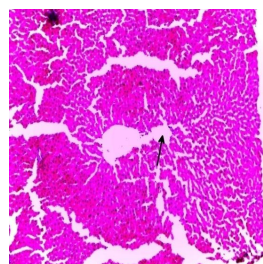


Fig. 2. (Group 2): Section shows areas of liver damaged (H&E, mag×100). A significant liver necrosis was observed, with different areas of liver damage as a result of CCl₄ induction and lack of treatment

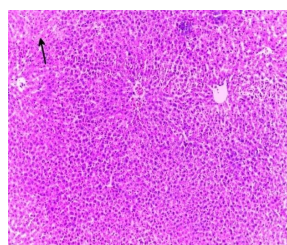


Fig. 3. (Group 3): Section shows areas of mild necrosis (H&E, mag×100). It shows a moderate regeneration of liver architecture by reduced level of necrosis, owing to the treatment of the rats with 200 mg/kg of *A. digitata* fruit pulp extract

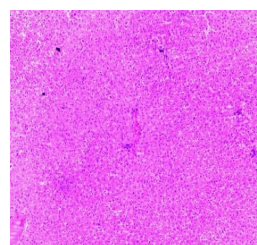


Fig. 4. (Group 4): Section shows no significant pathology (H&E, mag×100). It shows a significant regeneration of liver architecture when compared with figure 3, due to treatment with 300 mg/kg of *A. digitata* fruit pulp extract

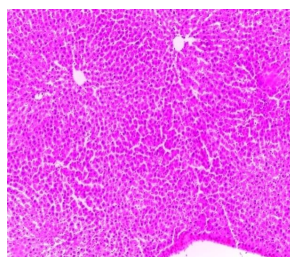


Fig. 5. (Group 5): Section shows no significant pathology (H&E, mag×100). A more significant regeneration of liver architecture was observed due to the administration of livoline drug

Table 2. Effect of treatment with the aqueous extract of *A. digitata* fruit pulp extract on CCl₄ Induced hepatotoxic rats' biochemical parameters

Group/parameters	ALT	AST	ALP	T/P	ALB	TBIL	DBIL
Group 1 N-control	24.6±3.51	26.4±6.43	39.2±6.42	41.6±5.68	29.6±11.24	39.6±7.37	28.2±13.42
Group 2 CCl ₄ only	71±10.17 ^b	69.8±9.65 ^b	87.8±8.90 ^b	76±7.18 ^b	61.8±9.78 ^b	72.2±12.39 ^b	63.4±10.57 ^a
Group 3 Test group	52.8±12.52 ^c	53.6±6.43 ^b	64.4±9.42 ^c	58±13.19 ^c	51.6±6.15 ^c	58.6±5.41 ^b	51.2±4.49 ^a
Group 4 Test group	42.6±10.36 ^c	41.2±8.47 ^c	55±9.19 ^c	46.2±2.58 ^c	37±13.19 ^c	43.8±6.22 ^c	35.6±13.56 ^b
Group 5 Standard drug	33.2±9.04 ^d	36.2±6.18 ^c	45.6±6.58 ^d	39±4.18 ^c	33±6.44 ^d	42.2±5.12 ^c	31.6±6.11 ^b

Values are expressed as mean±SD; n=5. Values with different superscript letter are significantly different at 95% confidence limit (p<0.05)

3.2 Discussion

3.2.1 Phytochemical analysis

The presence of certain phytochemical constituents in *A. digitata* like tannins, saponins, flavonoids, alkaloids, terpenes and glycosides indicates its hepatoprotective effect as some of the constituents have antioxidant activity.

3.2.2 Biochemical parameters

The efficiency of any hepatoprotective drug depend on its competence to either maintain the normal hepatic physiological mechanism that has been affected by a hepatotoxin or to reduce the harmful effects. The significant elevation in the rats marker enzyme and bilirubin in CCl₄ administered rats (Group 2) in this study is only a confirmation of previous reports on the hepatotoxicity of CCl₄ [27]. In most experiments involving the induction of liver injury in experimental animals, administration of CCl₄ elicited the elevation in the levels of liver marker enzymes (AST, ALT and ALP), albumin, total protein and bilirubin resulting in a significant hepatic damage [28]. The elevated levels of these biochemical parameters are direct reflection of alterations in the hepatic structural integrity.

The elevation of marker enzymes in rats administered with CCl₄ alone (Group 2) observed in this study is indicative of cellular leakage and loss of functional integrity in liver. In particular, the increase in the serum level of ALT is indicative of liver damage. These enzymes are located in the cell cytoplasm and are emptied into the circulation once the cellular membrane is damaged. However, the reduction in the levels of marker enzymes ALT and AST in rats treated with *A. digitata* fruit pulp extract as seen from the above table is also in agreement with the commonly accepted view that serum levels of transaminases return to normal with healing hepatic parenchyma and the regeneration of hepatocytes [28]. It is evident that an increase in bilirubin concentration in the serum or tissue is indicative of obstruction in the excretion of bile. Thus, the increased level of bilirubin observed in rats administered with CCl₄ alone (Group 2) could be attributed to liver damage. However, the decrease in bilirubin levels in treated rats (Groups 3, 4 and 5) indicates the reversal of liver damage by the *A. digitata* extract. It should be noted that, all the groups that were given CCl₄ (Groups 2, 3, 4 and 5) produced high values of

all the parameters when compared to Group I in correlation with previous researches [28]. ALP activity is related to the functioning of hepatocytes and increases in activity due to increased synthesis in the presence of increased biliary pressure [29]. The response of the liver to any form of biliary obstruction is to induce the synthesis of ALP and the main site of new enzyme synthesis is the hepatocytes adjacent to the biliary canaculi. Some of the newly formed enzymes enter the circulation to raise the enzyme level in serum [30].

A rise in plasma aminotransferase activities is a sensitive indicator of damage to cytoplasmic and/or mitochondrial membranes. Raised plasma transaminase concentrations are indicative of hepatocytes damage such as drug or toxin induced or viral hepatitis [31]. Estimating the activities of AST, ALT ALP, and TB in the serum are useful quantitative markers of the extent and type of hepatocellular damage [32]. The tendency of these enzymes to return to near normal in the extract-administered groups (Groups 3, 4 and 5) is a clear manifestation of hepatoprotective effect of *A. digitata* fruit extract. The results of this investigation indicated that, treatment of rats with the aqueous extract of *A. digitata* extract after CCl₄ administration caused a decline in hepatotoxicity in the rats. This is evidenced in the significant decrease in serum AST, ALT, ALP, TBIL, total protein (TP) and albumin (ALB) relative to the CCl₄ treated group as shown in the table above. The changes in albumin and total protein levels observed in CCl₄ treated rats and subsequent reversal caused by the administration of this different concentrations of *A. digitata* aqueous extract toward normalization is suggestive of the stabilization of endoplasmic reticulum leading to repair of impaired protein synthesis cause by CCl₄ with concurrent improvement of Kupffer cells [32]. Thus, aqueous extract of *A. digitata* showed ability to alleviate CCl₄ induced hepatotoxicity. These findings agree with the findings of Yadav, et al. [33] who reported increased ALB and TP concentrations after administration of aqueous extract of *Cissampelos periera* against CCl₄ induced hepatotoxicity in rats. It should also be noted that besides Group 2 which received only CCl₄, Groups 3 and 4 were treated with the extract of *A. digitata*, 200 and 300 mg/Kg body weight, respectively. However, the values of all the parameters were seen to be lower in Group IV (which took 300 mg/kg of the extract) when compared with group III (200 mg/kg), although the difference is not significant. However group V

rats (standard control) have lower values for all the parameters when compared to groups III and IV and with a significant difference when compared to induced control group (Group II). This result shows that the hepatoprotective or healing effect of the administered *A. digitata* was best at 300 mg/kg and it shows dose dependency. Meaning that the overall experimental results indicate that the biologically active phytoconstituents of the aqueous extract of *A. digitata* could alleviate the toxic action of CCl₄ in the liver. This healing or normalization process might also be associated with the high tendency of the liver tissue to rejuvenate after it has been injured or damaged.

3.2.3 Histopathological analysis

CCl₄ is a well known hepatotoxic industrial solvent. CCl₄ is commonly used for free radical induced liver injury. Liver is not the only target organ of CCl₄ but it also affects several organs of the body such as lungs, hearts, testes, kidneys and brain. It was reported from the investigation carried out on animal models of acute CCl₄ induced liver damage, it is now generally accepted that CCl₄ toxicity results from bioactivation of CCl₄ into trichloromethyl free radical by cytochrome P450 system in liver microsomes and consequently causes lipid peroxidation of membranes that leads to liver damage.

However, the cellular antioxidant action is reinforced by the presence of dietary antioxidants. Antioxidants and anti-inflammatory agents play a critical role against CCl₄ intoxication by scavenging active oxygen and free radicals and neutralizing lipid peroxides.

The histological findings (H&E) showed normal histological features in the liver hepatocytes of the control (group I) (see Fig. 1), while that of the hepatotoxic control (group II) presented marked areas of liver damage (black arrow), (See Fig. 2). On the other hand, liver features of the treated groups (III IV and V) showed moderate degeneration of hepatocytes (ranging from necrosis, mild to no significant pathology), figure shows mild necrosis for the 200 mg/kg *A. digitata* fruit extract treated rats (see Fig. 3), while the 300 mg/kg *A. digitata* fruit extract treated rats showed no significant pathology degeneration of hepatocytes (See Fig. 4). And the 200 mg/kg *A. digitata* extract treated rats showed no degeneration of hepatocytes, hence shows area of fibrosis. The hepatoprotective effects of *A.*

digitata fruit extract was confirmed by the comparative histopathological changes presented by the treated groups (III, IV and V) in relation to the features presented by those group I (control) and group II (untreated) (See Figs. 1, 2, 3, 4 and 5). Also, the observed efficacy of *A. digitata* fruit pulp extract in the treatment groups was dosage dependent (See Figs. 3, 4 and 5). However, on the effect of *A. digitata* fruit extracts on CCl₄ induced hepatotoxicity, this study shows that the CCl₄ induced hepatotoxic indications were to some degree reduced after 14 days of treatment with *A. digitata* fruit pulp extract in a dose dependent manner. These lessened hepatic damage by the administration of *A. digitata* fruit pulp extracts in group III, IV and V compared to that of group II, indicates recovery from CCl₄ hepatic damage and suggests its healing potentials as well.

4. CONCLUSION

The findings of this study indicates that the aqueous extract of *A. digitata* with a dose dependent effect exhibits significant hepatoprotective activity by reducing elevated levels of the biochemical parameters; and there was no significant difference compared to the standard drug (livoline). The histopathological findings reveal that *A. digitata* fruit pulp extract showed excellent protection on liver architecture, almost to the level of the normal control groups, validating its hepatoprotective effects in the experimental animals.

ACKNOWLEDGEMENT

The authors wish to acknowledge the support and assistance rendered by the Department of Biochemistry, Bayero University Kano.

COMPETING INTERESTS

Authors have declared that no competing interests exist.

REFERENCES

1. Hong JY, Lebofsky M, Farhod A, Jaeschke H. Oxidant stress-induced liver injury *in vivo*: Role of apoptosis, oncotic necrosis, and c-Jun NH₂-terminal kinase activation. *Am Journal Physiology*. 2009;296:G572-G58.
2. Chan AC, Fan ST, Lo CM, Liu CL, Chan SC, Yong BH, Chiu A, Lam BK. Liver

- transplantation for acute-on-chronic liver failure. *Hepatol Int.* 2009;3:571-581.
3. Cengiz N, Kavak S, Guzel A, Ozbek H, Bektaş HA, Erdoğan E, Balahoroğlu R. Investigation of the hepatoprotective effects of Sesame (*Sesamum indicum* L.) in carbon tetrachloride-induced liver toxicity. *Journal Membrane Biology.* 2013;246:1-6.
 4. Bansal AK, Bansal M, Soni G, Bhatnagar D. Protective role of Vitamin E pre-treatment on Nitrosodiethylamine induced oxidative stress in rat liver. *Chem Biol Interact.* 2005;156:101-111.
 5. Rivera H, Shibayama M, Tsutsumi V, Perez-Alvarez V, Muriel P. Resveratrol and trimethylated resveratrol protect from acute liver damage induced by CCl₄ in the rat. *J Appl Toxicol.* 2008;28:147-155.
 6. Haddad Y, Vallerand D, Brault A, Haddad PS. Antioxidant and hepatoprotective effects of silibinin in a rat model of nonalcoholic steatohepatitis. *Evid Based Complement Alternat Med.*; 2011. Article ID: 647903.
 7. Cerny D, Lekić N, Váňová K, Muchová L, Hořínek A, Kmoníčková E, Zídek Z, Kameníková L, Farghali H. Hepatoprotective effect of curcumin in lipopolysaccharide/galactosamine model of liver injury in rats: Relationship to HO-1/CO antioxidant system. *Fitoterapia.* 2011;82:786-791.
 8. Buchmann C, Prehler S, Hartl A, Vogl CR. The importance of baobab (*Adansonia digitata* L.) in rural West African subsistence-suggestion of a cautionary approach to international market export of baobab fruits. *Ecology of Food and Nutrition.* 2010;49:145-172.
 9. Addy R. Baobab Fruit Approved as Food Ingredient in US; 2009. Available:<http://www.nutraingredients-usa.com/content/view/print/2595742009> [Accessed on: 09/10/2016]
 10. Sanchez AC, Osborne PE, Haq N. Identifying the global potential for baobab tree cultivation using ecological niche modeling. *Agroforestry Systems.* 2010;80: 191-201.
 11. Adewale OB, Adekeye AO, Akintayo CO, Onikanni A, Sabiu S. Carbon tetrachloride (CCl₄)-induced hepatic damage in experimental Sprague Dawley rats: Antioxidant potential of *Xylopiya aethiopica*. Carbon tetrachloride (CCl₄)-induced hepatic damage in experimental Sprague Dawley rats: Antioxidant potential of *Xylopiya aethiopica*. 2014;3(2):1-6.
 12. Wickens GE. The baobab, Africa's upside-down tree. *Kew Bulletin.* 1982;37:171-202.
 13. Codjia JT, Fonton BK, Assogbadjo AE, Ekue M. Le Baobab (*Adansonia digitata*). Une Espèce à Usage Multiple au Bénin. Cecodi CBDD, Veco, SNV, FSA; 2001.
 14. Sidibe M, Williams JT. Baobab *Adansonia digitata*. Fruits for the Future, 4. International Centre for Underutilized Crops, Southampton, UK. 2002;100.
 15. Chadare FJ, Linnemann AR, Hounhouigan JD, Nout MJR, Van Boekel MA. Baobab food products: A review on their composition and nutritional value. *Critical Reviews in Food Science and Nutrition.* 2009;49:254-274.
 16. De-Caluwé E, Halamová K, Van Damme P. Baobab (*Adansonia digitata* L.): A review of traditional uses, phytochemistry and pharmacology. In: Rodolfo H, Simon JE, Ho CT, (Eds.), African natural plant products: New discoveries and challenges in chemistry and quality. Oxford University Press, USA. 2009;51-84.
 17. El-Rawy EM, Gergis SM, Bazaid S, El-Mougy SA. The immunostimulant effect of *Adansonia digitata* on the immune response of chicken vaccinated with avian cholera vaccine. *Journal of Egyptian Veterinary Medical Association.* 1997;57: 959-970.
 18. Ramadan A, Harraz FM, El-Mougy SA. Anti-inflammatory, analgesic and antipyretic effects of the fruit pulp of *Adansonia digitata*. *Fitoterapia LXV.* 1997;418-422.
 19. Trease GE, Evans WC. *Pharmacology.* 11th Edition, Bailliere Tindall, Ltd., London. 1978;60-75.
 20. Sofowora A. Medicinal plants and medicine in Africa. John Willey Spectrum, Ibadan-Nigeria. 1993;2:81-85.
 21. Sajedianfard J, Saeb M, Edalatpisheh M. Therapeutic effect of cimetidine on acetaminophen-induced hepatotoxicity in rabbits. *Comparative Clinical Pathology.* 2009;18(3):325.
 22. Musab AM, Imad MT, Abd-elwahab HM, Hozeifa MH. Hepatoprotective effect of *Adansonia digitata* L. (baobab) fruits pulp extract on CCl₄-induced hepatotoxicity in rats. 2015;4(8):368-377.
 23. Reitman S, Frankel S. A colorimetric method for the determination of serum

- glutamic oxalacetic and glutamic pyruvic transaminases. Am J Clin Pathol. 1957;28(1):56-63.
24. Roy AV. Rapid method for determining alkaline phosphatase. Clin. Chem. 1970;16: 431.
 25. Smith PK, Krohn RI, Hermanson GT, Mallia AK, Gartner FH, Provenzano MD, Fujimoto EK, Goeke NM, Olson BJ, Klenk DC. Measurement of protein using bicinchoninic acid. Anal Biochem. 1985;150(1):76-85.
 26. Auwioro OG. Histochemistry and tissue pathology techniques. 2nd Edition; 2010.
 27. Patrick-Iwuanyanwu KC, Wegwu MO, Okiyi JK. Hepatoprotective effects of African locust bean and Negro pepper in CCl₄ induced liver damage on wistar albino rats. Int. J. Pharmacol. 2010;6(5): 744-749.
 28. Adewale OB, Adekeye AO, Akintayo CO, Onikanni A, Sabiu S. CCl₄ induced hepatic damage in experimental Sprague dawley rats: Antioxidant potaential of *Xylopia aethiopica*. 2014;3(2):118-123.
 29. Muriel P, Garcipiana T. Silimarin protects against paracetamol induced lipid peroxidation and liver damage. J. Applied Toxicology. 1992;12,439-442.
 30. Burtis CA, Ashwood ER. Tiez fundamentals of clinical chemistry. (5th Ed) W. B. Saunders Company, Philadelphia. 2001;352-768.
 31. Crook MA. Clinical chemistry and metabolic medicine. 7th Edn. Arnold Ltd. 2006;253.
 32. Rekha R, Hemalatha S, Akasakalai K, Mudhukrisna CH, Vittal SB, Sundaram RM. Hepatoprotective activity of *Mimosa pudica* leaves against CCl₄ induced toxicity. J. Natural Products. 2009;2:116-122.
 33. Yadav MS, Kumar A, Sigh A, Sharma US, Sutar N. Phytochemical investigation and hepatoprotective activity of *Cissampelos pariera* against CCl₄ induced hepatotoxicity. Asian Journal of Pharmaceutical & Health Sci. 2011;1(3):106-110.

© 2020 Sa'id et al.; This is an Open Access article distributed under the terms of the Creative Commons Attribution License (<http://creativecommons.org/licenses/by/4.0>), which permits unrestricted use, distribution, and reproduction in any medium, provided the original work is properly cited.

Peer-review history:

The peer review history for this paper can be accessed here:
<http://www.sdiarticle4.com/review-history/54697>