



A Case Report of Post-extraction Central Cemento-Ossifying Fibroma

**Syeda Shadab Farha^{1*}, Sonia Kaur Sodhi², Firdous Shaikh³,
Huma Md Saleem³ and Nida Shaikh⁴**

¹Oral Medicine and Radiology, Civil Hospital, Bangaluru, Karnataka, India.

²Oral Medicine and Radiology, Department of OMDR, CSMSS Dental College and Hospital, Aurangabad, Maharashtra, India.

³Oral Medicine and Radiology, Consultant Oral Physician and Maxillofacial Radiologist, India.

⁴Dental Surgeon, India.

Authors' contributions

This work was carried out in collaboration among all authors. All authors read and approved the final manuscript.

Article Information

Editor(s):

(1) Dr. M. Jaya Nagendra Krishna, Kamineni Institute of Dental Sciences, India.

(2) Dr. Roberta Gasparro, University of Naples Federico II, Italy.

Reviewers:

(1) V. S. N. Vithanaarachchi, University of Peradeniya, Sri Lanka.

(2) R. Pradeep Kumar, Saveetha Institute of Medical and Technical Sciences, India.

(3) K. B. Naziya, University of Mysore, India.

Complete Peer review History: <https://www.sdiarticle4.com/review-history/72851>

Case Report

Received 22 June 2021

Accepted 02 September 2021

Published 21 September 2021

ABSTRACT

Rare fibro-osseous lesions that affect the jaw bones and are included in the group of mesodermal odontogenic tumors, Cemento-Ossifying fibromas are usually reported in the middle age with a female predominance unlike that reported in this case. Mostly occurring in the mandible and presents as a painless swelling. A traumatic event may act pre disposing factor or a trigger for development and progression of such lesions of jaw. Considering similar event, exodontia, one of the routine minor surgical procedure performed in a dental setup, might pose as a either pre disposing factor or a trigger. The present article intends to establish the connection between occurrence of such an unlikely case of Central Ossifying fibroma of the mandible hypothesized to have been triggered post extraction.

Keywords: *Cemento ossifying fibroma; non odontogenic tumor; fibro-osseous lesions; post extraction swelling.*

1. INTRODUCTION

Cemento ossifying fibroma (COF) is the most common benign fibro osseous neoplasm of the maxillofacial region. Described by Menzel in 1872 and appointed by Montgomery in 1927, this lesion tends to occur in the second and third decades of life. Its female to male ratio being 4:1 and most common location is the mandible, with 70-90% of all cases [1-2]. The general clinical presentation has usually been spherical or ovoid, expansive, deforming, painless jaw bone mass which may displace the roots of adjacent teeth with or without root resorption [3]. On a radio graph, it shows a number of patterns depending on the degree of mineralization, manifesting as a well delineated unilocular lesion with variable amounts of radio opaque material [4]. However, there are other lesions of the maxillary bones that need to be included in the differential diagnosis, such as focal cementum-osseous dysplasia, asteroid osteoma, and fibrous dysplasia [5]. Once completely excised, COF does not usually recur [6]. There is a supposition that previous tooth extraction or periodontitis might provide a stimulus or that the formation of ossifying fibromas might be simply linked to a disturbance of bone maturation of congenital origin which most likely explains the trigger factor in the present case [7]. Considering the rare presentation of this lesion in a male patient and the occurrence post extraction we intend to report this case to provide a connection between these two events.

2. CASE REPORT

A 22-year old male patient reported to our institute with the chief complaint of pain and swelling in the lower right back region of jaw since 3-4 months.

History of present illness: Patient gave history of extraction with #46, around 5-6 months back followed by #47, post root canal treatment 4-5 months back. Subsequently a month or so on extraction of 47 he experienced a painless swelling in the region of extraction in his mouth, of sudden and insidious onset, which gradually expanded to the present size and caused patient discomfort.

2.1 Intra-oral Examination

On inspection: A pale pink swelling was evident on intra oral examination on the alveolar ridge of

right side of size approximately 1.5x 2.5 mm in dimensions that extended antero-posteriorly from distal aspect of #45 to mesial aspect of #48 and bucco-lingually from buccal cortical plate to lingual cortical plate.

On palpation: The intra oral swelling was afebrile, tenderer on the lingual aspect than on the buccal aspect, bony hard in consistency with smooth surface texture and fixed to the underlying structure. It was non fluctuant and non compressible in nature. All the teeth at the site of concern were missing during the time of examination.

2.2 Investigations

Pre-extraction records: Patient produced an *orthopantomogram* which was taken at the time extraction of #47 was planned, post-extraction to #46. This OPG revealed a mixed radio-opaque radio-lucent lesion in the apical area of #47 extending towards edentulous region of 46. Also the soft tissue shadow in the region of #46 seemed to be more prominent. Radio-opacity seen along the coronal and radicular portion of #47 suggestive of root canal filling. Bone loss evident in furcation area with #47.

Investigations post examination: *Intra-oral peri-apical radiograph:* revealed a mixed radio-opaque and lucent lesion in the area of interest, so an occlusal view and an OPG were advised for further diagnosis of the lesion.

Mandibular occlusal topographic view: showed a single well circumscribed well capsulated lesion on right alveolar ridge in relation to #46 and #47. Lesion was mixed radiopaque and radiolucent structure with cortical bone expansion in the region of #46 #47.

An orthopantomogram: revealed a mixed radiopaque-radiolucent lesion which was distal to the lower right second premolar was visible. It extended from the alveolar crest to the inferior borders of the mandible suggestive of a mixed lesion of jaw.

Provisional diagnosis: Central ossifying fibroma

Differential diagnosis:

1. Peripheral ossifying fibroma
2. Fibrous dysplasia.

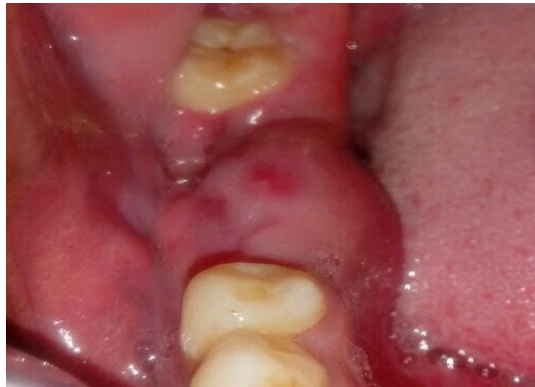

Fig. 1. Intra-oral swelling

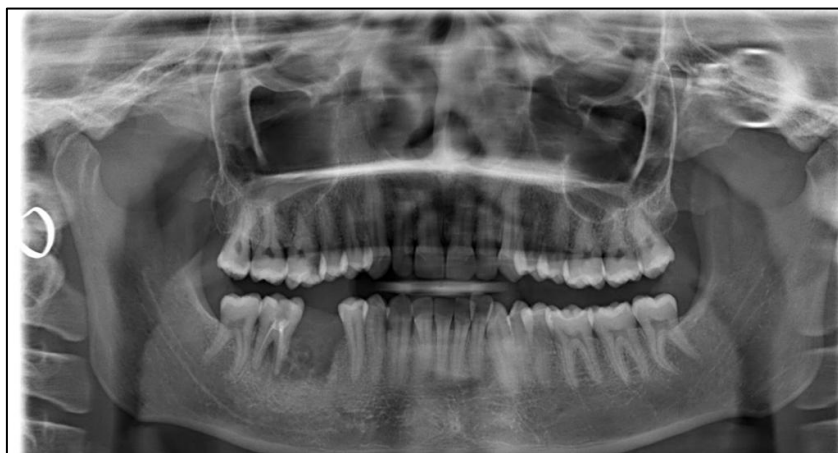

Fig. 2. Pre extraction orthopantomogram

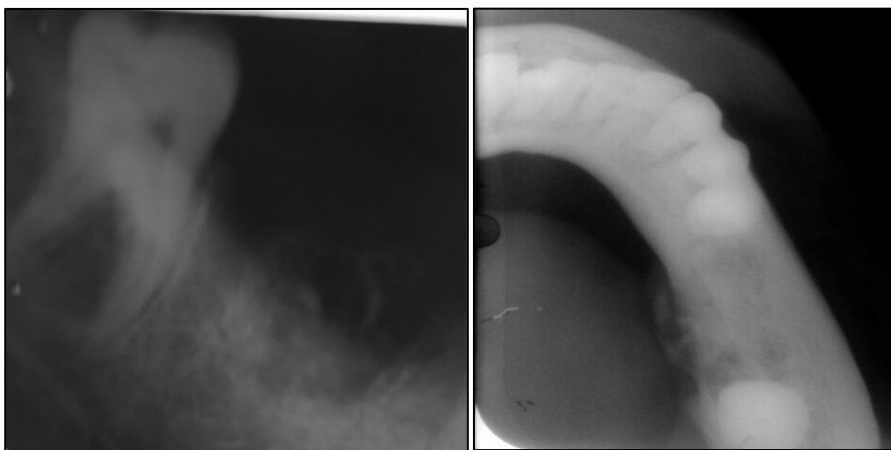


Fig. 3. IOPA and Occlusal views

2.3 Biopsy Report

Histo-pathological section showed numerous woven bony trabeculae in a fibrous connective tissue core. Woven bony trabeculae were surrounded by osteoblasts. At places, osteocytes

were noted within osteocytic launae. Fibrous tissue was evident within connective tissue core suggestive of ossifying fibroma. Based on the clinical features, radiography and histopathology, the final diagnosis was central ossifying fibroma with #46 # 47 region. Refer Fig. 6.

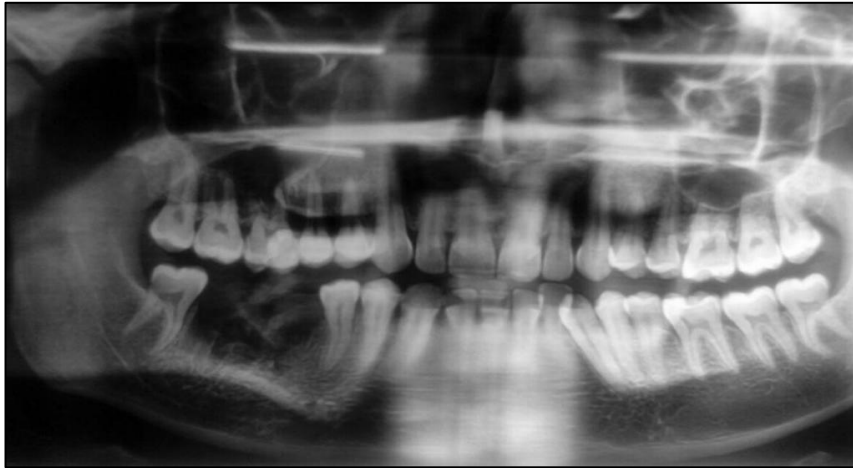

Fig. 4. OPG Post extraction

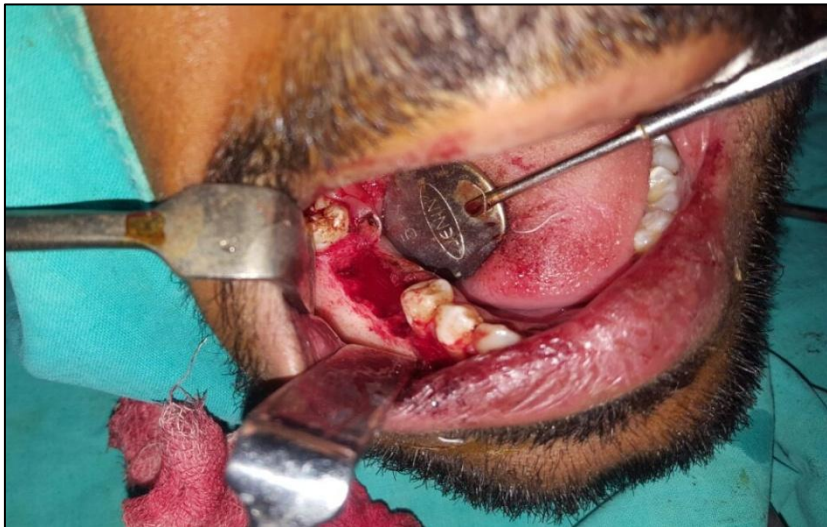

Fig. 5. Intra operative picture

3. DISCUSSION

Central Ossifying Fibroma (COF) is a benign osseous neoplasm which consists of highly cellular, fibrous tissue with varying amounts of calcified tissue, which resembles the bone, the cementum or both [8-9]. Branon and Fowler were the first to use the term 'ossifying fibroma' (OF) in place of COF and the recent WHO (2005) edition of the classification of odontogenic neoplasms has replaced the term COF with OF.

The WHO, classifies Cemento-ossifying fibroma, as a fibro-osseous neoplasm included among the non-odontogenic tumors derived from the mesenchymal blast cells of the periodontal ligament, with a potential to form fibrous tissue,

cementum and bone or a combination of such elements [10].

Fibro-osseous lesions (FOL) are a group of conditions which are characterized by the replacement of normal bone by fibrous tissue, which contains a newly formed, mineralized product [11]. They were initially classified into three main categories namely, fibrous dysplasia, fibro-osseous lesions such as ossifying and cementifying fibroma, and fibro-osseous neoplasms such as juvenile active ossifying fibroma. In recent years, these lesions were reclassified into fibrous dysplasia, reactive lesions arising in the tooth-bearing area, and fibro-osseous neoplasms such as cementifying and ossifying or Cemento-ossifying fibroma [12].

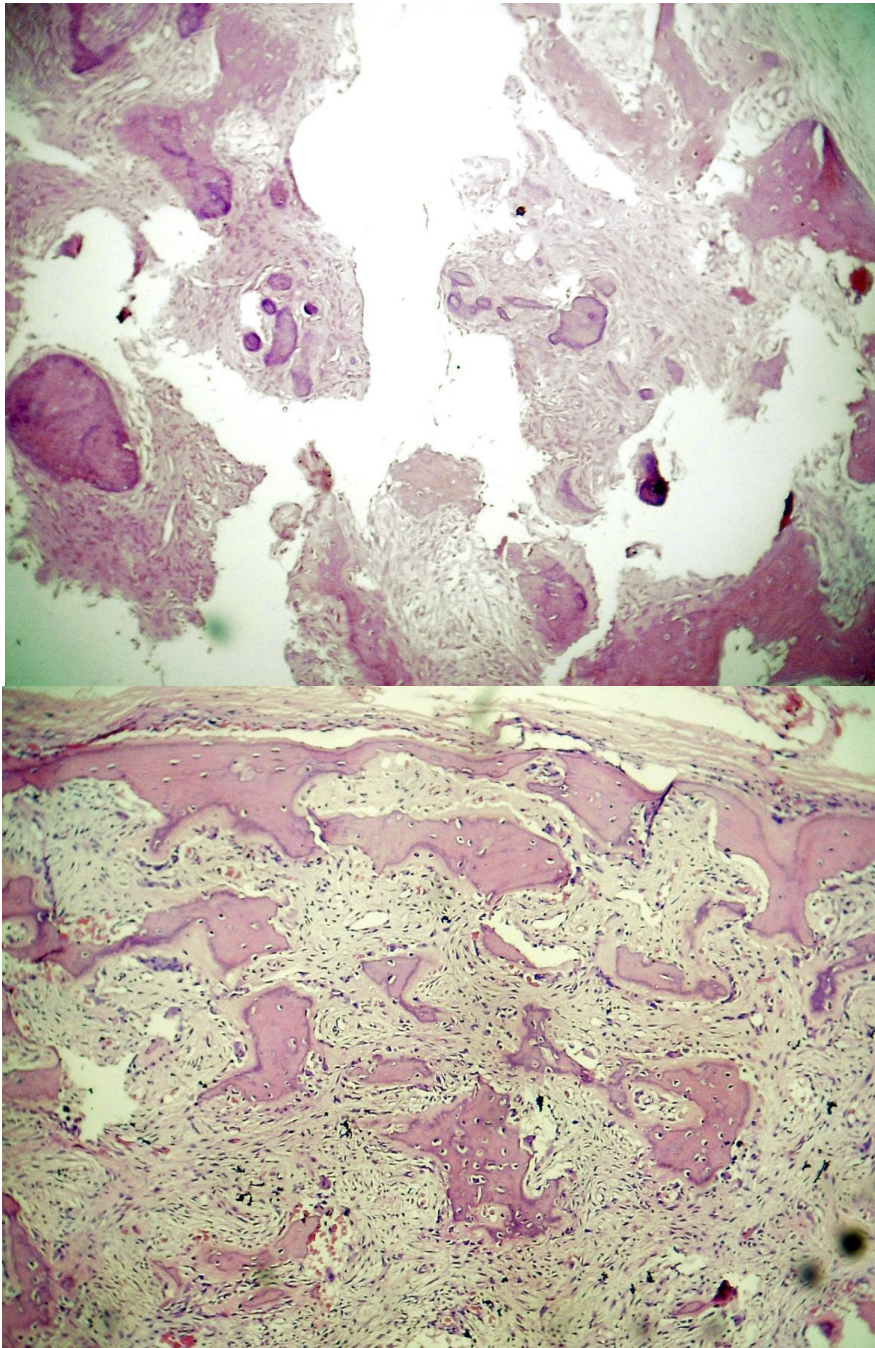


Fig. 6. Histo-pathology slides

Fibroblastic gingival lesions have been given a number of names, such as epulis, peripheral fibroma with calcification, peripheral ossifying fibroma, calcifying fibroblastic granuloma, peripheral cementifying fibroma, peripheral fibroma with cementogenesis and peripheral Cemento-ossifying fibroma, which indicates that there is a lot of controversy surrounding the classification of these lesions [13].

MacDonald-Jankowski described three stages of COF, based on the radiographic features; an initial radiolucent stage, then a mixed stage and eventually, a sclerotic appearing stage [14]. Review of the literature has revealed that COFs are usually seen in the third and fourth decades of life unlike in the present case. Most of the studies showed a female predominance, but in this we have reported a male patient with the lesion [15].

Ossifying Fibromas are slow-growing lesions and because of the slow growth, the cortical plates of the bone and the overlying mucosa or skin are invariably intact. Ossifying fibromas are usually solitary, but bilateral as well as multiple familial ossifying fibromas have also been reported [16]. Classically, the patients present with a painless swelling, though with time, the lesion may become large enough to cause facial deformation [17]. Root divergence, displacement of teeth in the tooth-bearing region or root resorption may be associated with the tumor, but in the present case it was found to be associated with edentulous region [18].

Radio graphically, two basic patterns have been defined: one characterized by the presence of a unilocular or multilocular radiolucent image, and another showing mixed density due to a variable internal amount of radiopaque material. The latter one relevant with the present scenario. They are typically well circumscribed and maintain a spherical shape, expand the surrounding cortical bone without cortical perforation, and may cause tooth divergence [19].

Histologic differentiation between osteoid and cementum is difficult. Most pathologists feel that central cementifying fibromas and central ossifying fibromas arise from the same progenitor cell but produce variable amounts of bone and cementum within any one lesion. The hybrid term central Cemento-ossifying fibroma has evolved to indicate the likely presence of both types of tissue within the same lesion because of the difficulty in being able to distinguish reliably immature bone from immature cementum and because of the presence of both of these substances in many of the lesions. Thus, central Cemento-ossifying fibroma, as in the present case, is the most accurate histologic term, but it can be interchanged with either central ossifying fibroma or central cementifying fibroma. There is no apparent clinical or radiologic difference between the central cementifying fibroma and central ossifying fibroma, so the hybrid central Cemento-ossifying fibroma works for radiology as well [20].

The dilemma of the present case as of the extraction being triggering factor for pathogenesis of the lesion is substantiated by the supposition stated by Daniel Trivelato da Silveira et al. [7] that tooth extraction or periodontitis might provide a stimulus. It also clarifies that Ossifying fibromas are formed from pluripotent

mesenchymal cells that originate from the periodontal ligament which are capable of forming bone tissue and cement.

The treatment of choice for of is surgical excision as done for the present patient. Small and well demarcated lesions can be excised by enucleation and curettage, whereas larger lesions, that show a more aggressive pattern, especially in the maxilla, require radical surgery within healthy margins. Recurrence rate varies from 6% to 28% of patients with mandibular OFs. The recurrence rate of maxillary OFs is unknown, but it is likely to be higher because of the greater difficulty of their surgical removal and larger size at the time of presentation. If relapse is identified in the course of follow-up, conservative resection is obligate [21].

4. CONCLUSION

Ossifying fibroma, a fibro-osseous lesion has been generally been reported to occur in female patients unlike in the present case. Sparse literature is available to provide correlation between its occurrence and progression post extraction. However etiology of development of Ossifying fibroma has been found to be that of the periodontium and extraction may be considered to act like a trigger for its pathogenesis. More cases of varied etiology and incidences need to be reported in literature.

CONSENT AND ETHICAL APPROVAL

As per international standard or university standard guideline Patient's consent and ethical approval has been collected and preserved by the authors.

COMPETING INTERESTS

Authors have declared that no competing interests exist.

REFERENCES

1. Montgomery AH. Ossifying fibromas of the jaws. *Archives of Surgery*.1927;15:30.
2. Javier Silvestre-Rangil, Francisco Javier Silvestre, Juan Requeni-Bernal. Cemento-ossifying fibroma of the mandible: Presentation of a case and review of the literature. *J Clin Exp Dent*. 2011;3(1):66-9.
3. Huebner GR, Brenneise CV, Ballenger J. Central ossifying fibroma of the anterior

- maxilla. Report of a case. J Am Dent assoc. 1988;116:507–10.
4. Matheus Henrique Lopes Domingue et al. Extensive Presentation of Central Ossifying Fibroma Treated with Conservative Surgical Excision. Hindawi Publishing Corporation Case Reports in Dentistry; 2014, Article ID 204258, Available: <http://dx.doi.org/10.1155/2014/204258>
 5. Issrani R, Mathur S, Chandra S, Prabhu N. Central Cementifying Fibroma of Mandible - A Case Report with Literature Review. Journal of Dentistry and Oral Care Medicine. 2015;1(1). ISSN: 2454-3276
 6. MacDonald-Jankowski DS. Ossifying fibroma: a systematic review. Dentomaxillofac Radiol. 2009;38:495-513.
 7. Daniel Trivelato da Silveira et al. Ossifying fibroma: report on a clinical case, with the imaging and histopathological diagnosis made and treatment administered. Revista Brasileira de Ortopedia. 2016;51(1):100-104.
 8. Liu Y, You M, Wang H, Yang Z, Miao J, Shimizutani K, Koseki T. Ossifying of the jaw bone: a study of 20 cases. Dentomaxillofac Radiology. 2010;39:57-63.
 9. Bal Reddy, P., B. Sridhar Reddy, N. Prasad, G. Kiran and Karthik Patlolla. Central Ossifying Fibroma of the Mandible: An Unusual Case Report. Journal of Clinical and Diagnostic Research, (Suppl-1), 6(3); 2012: 539-541.
 10. Deb R, Mukherji S, Singh, Kumar V. Cemento-Ossifying Fibroma of Mandible-A Case Report. Saudi J. Oral. Dent. Res. 2017;2(5);2017:119-122
 11. Waldron CA. Fibro-osseous lesions of the jaws. J Oral MaxillofacSurg. 1985;43:249–62.
 12. Ong AH, Siar CH. Cemento ossifying fibroma with mandibular fracture. Case report in a young patient. Aust Dent J. 1998;43:229-33.
 13. Farquhar T, MacLellan J, Dymont H, Anderson RD. Peripheral Ossifying Fibroma: A Case Report. J Can Dent Assoc. 2008;74(9):809-812.
 14. MacDonald-Jankowski DS. Cemento-ossifying fibromas in the jaws of the Hong Kong Chinese. Dentomaxillofac Radiol. 1998;27:298–304.
 15. Eversole LR, Leider AS, Nelson K. Ossifying fibroma: A clinicopathologic study of sixty-four cases. Oral Surg Oral Med Oral Pathol. 1985;60:505–11.
 16. Yih WY, Pederson GT, Bartley MH. Multiple familial ossifying fibromas: Relationship to other osseous lesions of the jaws. OralSurg Oral Med Oral Pathol. 1989;68:754-8.
 17. Summerlin DJ, Tomich CE. Focal cemento-osseous dysplasia: a clinicopathologic study of 221 cases. Oral Surg Oral Med Oral Pathol. 1994;78:611–20.
 18. MacDonald-Jankowski DS. Ossifying fibroma:a systematic review. Dentomaxillofac Radiol. ;38:495-513.
 19. Bagi MA, Bokhari K, Nager MA, Basheer SA, Assiri MAM. Cemento ossifying fibroma involving mandible. Int J Experimental Dent Sci. 2013;2:127-9.
 20. Tamiolakis D, Thomaidis V, Tsamis I, Alexiadis G, Seretis K. Clinical, radiological and histological correlation in the diagnostic work-up of cemento ossifying fibroma of the maxilla: apropos a case. Chirurgia (Bucur). 2007;102:359-62.
 21. Ramesh et al. Ossifyinf fibroma, a case report. Journal of Dental and Medical Sciences. 2017;16(5):63-66.

© 2021 Farha et al.; This is an Open Access article distributed under the terms of the Creative Commons Attribution License (<http://creativecommons.org/licenses/by/4.0>), which permits unrestricted use, distribution, and reproduction in any medium, provided the original work is properly cited.

Peer-review history:
The peer review history for this paper can be accessed here:
<https://www.sdiarticle4.com/review-history/72851>